










Case Report

400 Gramme on Skull Base and Face: Complete Removal and Reconstruction

Ibrahim Dao^{1, 2, 3, *} , **Ibrahima Traoré⁴**, **Michel Kohoun⁴**, **Astride Somda⁵** , **Salah Sow⁶** , **Nasser Doukouré⁷**, **Narcisse Ouedraogo¹** , **Ousmane Ouattara¹** , **Frédéric Bako¹** , **Abdoulaye Sanou^{5, 8}** , **Elie Dibloni Nassoum^{5, 8}** , **Arsène Tossou^{5, 8}** , **Rasmané Beogo⁴**, **Patrick Wendpouiré Hamed Dakouré^{1, 2}**

¹Department of Orthopedic Surgery, University Hospital Souro Sanou, Bobo Dioulasso, Burkina Faso

²Higher Institute of Health Sciences, Nazi Boni University, Bobo Dioulasso, Burkina Faso

³Department Surgery, Military Hospital Colonel Major Tanguet Ouattara, Bobo Dioulasso, Burkina Faso

⁴Department of Stomatology and Maxillofacial Surgery, University Hospital Souro Sanou, Bobo Dioulasso, Burkina Faso

⁵Department of Neurosurgery, University Hospital Yalgado Ouedraogo, Joseph Ki-Zerbo University, Ouagadougou, Burkina Faso

⁶Department of Radiology and Medical Imaging, University Hospital Yalgado Ouedraogo, Joseph Ki-Zerbo University, Ouagadougou, Burkina Faso

⁷Department of Ophthalmology, University Hospital Souro Sanou, Bobo Dioulasso, Burkina Faso

⁸Department of Neurosurgery, Military Hospital Capitaine Halassane Coulibaly, Ouagadougou, Burkina Faso

Abstract

Background: Huge craniofacial tumors represent a surgical challenge not only for high risk of intraoperative damage of the brain and sense organs of the face, but also for esthetical issues which may occur postoperatively. This surgery is riskier when these processes are represented by massive compact bone such as osteomas. **Case presentation:** A young patient with huge disfiguring osteoma of anterior skull base extended to sphenoidal, frontal, maxillary sinuses as well as in orbits benefit for a complete removal with craniofacial reconstruction through a surgical teamwork including neurosurgeon, maxillofacial surgeon and ophthalmologist; with an overt satisfactory cosmetic result. Preoperative planning is reported as well as the intraoperative procedure and the postoperative reconstruction and follow up. **Conclusion:** Craniofacial osteoma represents a surgical and cosmetic challenge for their resection. This resection is tailored through sophisticated devices such as preoperative 3D (3 dimension) printed model, intraoperative neuronavigation, and the use on custom-made bone. In place where this reported patient is managed, these tools are unavailable. Thus, priority should be given to teamwork with accurate preoperative planning and manually confectioned cranioplasty. Endoscopic approach for these processes gained more and more indication in the resection of these craniofacial and skull base osteomas. Since this device require a learning curve, laboratory training for is proper using as well as in microneurosurgery techniques is highly recommended. A hope is encountered though the humanitarian implication of some organization and universities.

*Corresponding author: dao.ibrahim@gmail.com (Ibrahim Dao)

Received: 23 April 2024; **Accepted:** 10 May 2024; **Published:** 24 May 2024



Copyright: © The Author(s), 2024. Published by Science Publishing Group. This is an **Open Access** article, distributed under the terms of the Creative Commons Attribution 4.0 License (<http://creativecommons.org/licenses/by/4.0/>), which permits unrestricted use, distribution and reproduction in any medium, provided the original work is properly cited.

Keywords

Osteoma, Craniofacial Sinuses, Skull Base, Orbit, Cranioplasty, Endoscopy, Microneurosurgery Laboratory

1. Introduction

The incidence of craniofacial osteomas accounts for 0.4 to 1%. These are slow growing benign processes and are commonly discovered incidentally in small size osteomas. Giant craniofacial osteoma defined as greater than 3 cm in diameter or weighing more than 110 g are very rare and responsible for brain and sense organs compression as well as esthetic disorder [1-3]. Surgery is challenging in these latter cases not only for vital and functional result but also by maintaining a cosmetic skull profile [3]. Some authors advocate partial removal to avoid unacceptable complication in giant osteomas [1]. High surgical platform and preoperative 3-D model are sometimes requiring for an accurate resection and tailored cranioplasty [3]. This case is reported to describe the surgical technique and postoperative management of a giant craniofacial and Skull base osteoma with good cosmetic result in a resource limited country with moderate platform and manually confectioned cranioplasty.

2. Case Report

This 17-year-old man without past medical history was admitted in for a progressive right eye proptosis with hypertelorism associated to a painless mass growing at the right medial canthus. He also complained for moderate chronic headache and nasal obstruction. This was responsible for an important disfigurement and negative social impact on the patient. Physical examination showed a hard mass in consistency, immobile and covered by normal skin at the level of the medial canthus. This lesion results in a lateral deviation of the right eye with an increased distance between the nasal bridge and the medial canthus of the right eye. A smaller lesion with the same feature was noticed at the superior part of the medial canthus of the left eye with less important lateral deviation of this eye and without proptosis. Both eyes displayed a limitation of their movement and right eye was almost immobile. Computed tomography scan (CT scan) revealed a craniofacial multilobulated bony mass extended from the frontal sinuses to the right maxillary sinus in the vertical axis; from one orbit to another in the horizontal axis and occupying all the extend of anterior skull base till the sphenoid sinus. This mass was measuring 8 Cm x 6 Cm x 8 Cm respectively (Figure 1). There was a compression of the frontal lobe and an appearance of maxillary, frontal and sphenoid mucocoele. Visual acuity as well as fundoscopy was normal.

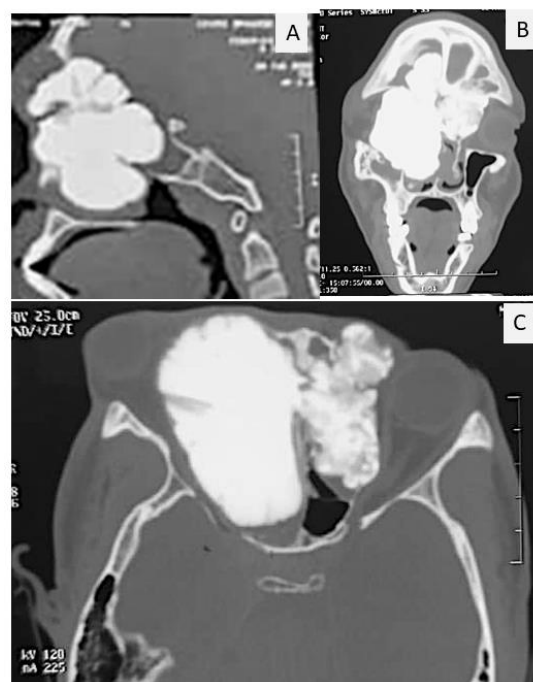

Figure 1. Craniofacial CT scan showing a multilobulated bony mass of the anterior skull base, extended to the sinuses, orbit and nasal cavities.

2.1. Surgical Technique

2.1.1. Planning

A multidisciplinary team of neurosurgeons, maxillofacial surgeon and ophthalmologist planned the surgical procedure after discussion with the patient and his family.

This team strategized on the removal of the osteoma, which was compared to a building on sagittal view. The ground floor was constituted with one room represented by the maxillary sinus and anterior skull base part. The first floor with two rooms was represented by the frontal sinus part anteriorly and the intracranial part posteriorly. Thus, 3 steps were drawn: first of all, a removal of the frontal sinus part (anterior room of the first floor); then disconnection of the intracranial part from the skull base portion allowing its removal (Last room of the first floor); finally, en bloc removal of the anterior skull base part which was extended in the right maxillary sinus and more than half of the right orbit (ground floor) (Figure 2).

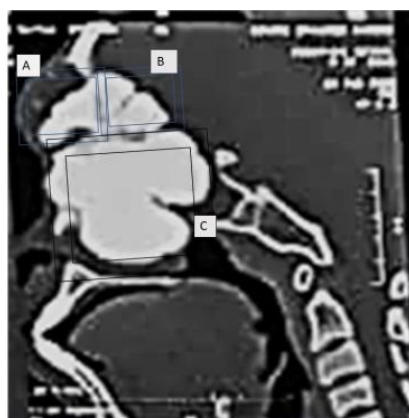

Figure 2. Surgical planning: Anterior room of the first floor (A), posterior room of the first floor (B) and the ground floor (C).

2.1.2. Incision and Removal Procedure

The patient on general anesthesia was placed supine with his head on horseshoes head holder. Preparation of the head and the face was achieved. A bicoronal incision from tragus to tragus allowed the exposition of frontal bone, which anterior wall was thinned. A transfrontal sinus approach revealed mucocoele and two attached bony processes, one in each sinus, with the left sinus part extending into the left orbit. This frontal sinus part was removed with osteotome and gave access to the intracranial part. This latter showed compression on the frontal lobe and a blunt dissection detached its superior surface from the dura matter, which was intact. Then a disconnection from the anterior skull base with an osteotome was achieved. To realize a complete disconnection of the ground floor part, an inferior palpebral approach to the right maxillary sinus was done. This allowed its detachment from the walls of the maxillary sinus and some outgrowth satellite smaller osteomas extended toward the nasal cavity were removed. Ultimately, the biggest part was removed en bloc. It should be noted that the extension of this part from the right orbit to the maxillary sinus had destroyed the floor of the orbit (**Figure 3**).

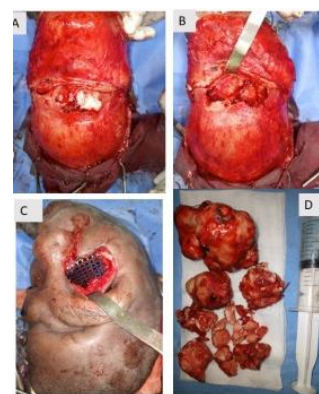


Figure 3. Intraoperative images showing mucocoele (A), osteoma in frontal sinuses (B), reconstruction of the floor of orbit (C) and osteoma resection at the end of the surgery (D).

2.1.3. Reconstruction and Closure

A reconstruction of the floor of the right orbit was performed with platinum mesh plate, then a skin closure of the bicoronal and the inferior palpebral approach.

2.2. Cranioplasty and Operative Result

The patient was extubated at the end of the surgery and transferred to the intensive care unit for 24 hours, then at the regular hospitalization ward. Postoperatively, the propotosis was changed into enophthalmos. However, there was a normal visual acuity and oculomotricity on both eyes without neurological deficit. The lack of the frontal bone resulted in the depression of forehead. Patient was discharged at hospital day 5 and six month later, a manually tailored cranioplasty with acrylic cement was performed to close the frontal defect and re-establish the normal curve of the forehead. Another 6 months follow up after cranioplasty showed an asymptomatic patient with an overt satisfactory cosmetic result. Moreover, the patient was more confident on himself with a positive psychological and social state on him and his family (**Figure 4**).

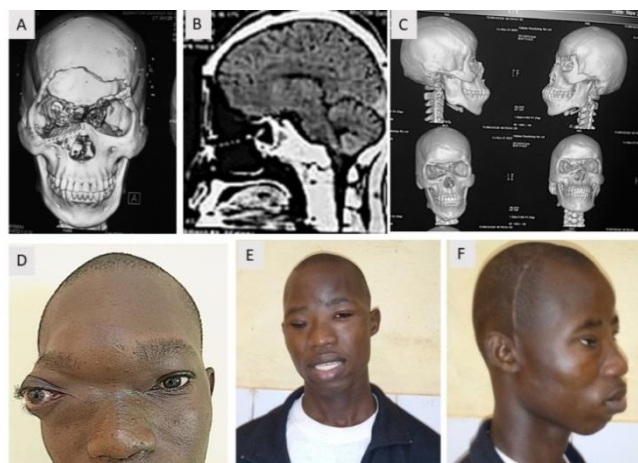


Figure 4. Post operative CT Scan showing a complet removal of the osteoma (A, B) with cranioplasty (C). preoperative picture (D) comparatively to post operative shows the cosmetic result.

3. Discussion

Primary orbital osteomas are extremely rare and most of them are commonly paranasal sinus osteoma invasion [1, 4]. These sinuses site in descending order of frequency is; Frontal (80%), ethmoid (15%), maxillary (5%), and sphenoid sinuses (1%). Haddad et al propose a clinico-anatomic classification based on the topographic distribution, the frequency and symptomatology of cranial osteoma into four categories: intraparenchymal, dural, skull base and skull vault [4]. This case reported, was invaded all of the paranasal sinuses as well as the orbits, the skull base, the cranial vault with great compression on the brain parenchyma through the dura matter. Giant osteomas are referred to be greater than 3 Cm in diameter or 110 g in weight. Thus, this reported case weighting 400 g (near a half kilogram) with such extension is a giant craniofacial osteoma. Small paranasal sinuses osteomas are often incidentally found [1, 3, 5]. However, larger tumor can present with mass effect or complications such as ophthalmological, sinus related or intracranial. Ophthalmological complications are rare and consist of proptosis, diplopia, ptosis [6, 7]. Very rarely, visual loss and apiphoria can occur due to compression of lacrimal sac by osteoma. Sinus related complications of frontal osteoma include frontal sinusitis, mucocele and vacuum 'sinus' syndrome due to extension of osteoma into the anterior cranial fossa through the posterior wall of the frontal sinus or the cribriform plate, and can lead to pneumocephalus, meningitis, or cerebral abscess [8-11]. The patient in this reported case was suffering from unaesthetic aspect proptosis, hypertelorism and nasal obstruction as ophthalmological and sinus related complications respectively. According to literature, a tumor with more than 50% of bony orbit involvement is prone to cause irreversible visual loss [1] as well as sphenoid or posterior ethmoid osteomas result most of the time in orbital apex syndrome [12]. Albeit, the right orbit involvement in this paper was greater than 50% with an extension to posterior ethmoid and sphenoid; vision, visual acuity and fundoscopy were normal. This may be explained by the slow growing duration of the osteoma, the hypertelorism and proptosis which may relatively decrease the pressure on the eye ball. Indeed, the growth rate is reported to be 1.66mm/ Year [1]. However, this normal vision represented a huge stress for the postoperative outcome which should be free of complication above all preservation of visual function. Small paranasal sinuses osteomas can be easily managed either endoscopically or by open surgery [1, 3, 5]. Surgery is recommended in cases of significant tumor growth accompanied by the appearance of clinical symptoms, involvement of orbit or anterior skull base and the resulting complication [12-15]. The case reported in this paper was thus eligible for surgery according to these above criteria and to correct the cosmetic prejudice. Some authors reported endoscopic surgery for giant osteomas located into sinus [16-18]. Osteomas located near the frontal recess, and maxillary os-

teoma located in the upper part of the maxillary sinus can be treated via endoscopic approach [18, 19]. Based on statistical analysis of literature data, Humeniuk-Arasiewicz et al concluded that the average size of osteomas excised endoscopically and those removed by external approach does not differ statistically, in case of osteomas located both in the ethmoidal cell ($p=0.2691$) and the frontal sinuses ($p=0.5891$). The choice of method in these latter cases appears to be independent of the osteoma size and the decision is likely to be taken based on the past experience of the surgeon, available equipment and knowledge of different surgical techniques [5]. Whereas, multicompartmental osteomas such this case report should be excised via external approach [20]. This may require a team work like in this paper (Neurosurgeon, maxillo-facial surgeon, ophthalmologist). Post-operative morbidity include meningitis, subdural emphysema, brain abscess, nasal and sinus complications (epistaxis, septal perforation, chronic sinusitis, and mucocele), ophthalmologic complication (epiphora, strabismus, diplopia, ptosis, infection and even loss of vision), and poor cosmetic outcomes. In the reported case carried by this paper a complete removal was performed and the cosmetic result was excellent with vision preservation despite a moderate enophthalmos due to a removal of the osteoma at the posterior part of the orbit. In developed countries, 3D printed model can be used to plane the surgical approach and custom-made bone can be usually used for cranioplasty. However, in resources limited countries, a multidisciplinary preoperative discussion, an intraoperative team work and a manual confectioned cranioplasty may lead to the same satisfactory result. Despite the commonly solitary behavior of sino-orbital osteoma, surgeons should keep into their mind a possible association with Gardeners' syndrome, an autosomal dominant subtype of familial adenomatous polyposis (FAP) characterized by multiple polyps in the colon, with extracolonic soft tissues which may show a progression to malignancy in near 100%. In this case report, investigations about this condition were negative.

4. Conclusion

A complete removal of multicompartmental giant craniofacial osteomas remains gratifying when a good post-operative outcome is achieved as well as in functional and cosmetic field. To reach this result preoperative 3D-printed technology, accurate intraoperative resection device such as neuronavigation guidance, and postoperative custom-made bone is an effective armamentarium in high income countries. The lack of these tools in low-income countries can be balanced with a multidisciplinary preoperative and intraoperative teamwork associated with a post-operative manually tailored cranioplasty with acrylic cement to restore an optimal cosmetic profile. For localized even giant osteomas (sinus, orbit.), many authors consider endoscopic resection to be the new modality of choice for resecting such lesions [21]. Thus, every surgeon dealing with craniofacial

osteomas should be trained to be comfortable in the mastering of this endoscopic surgery. This requires laboratory training in proper endoscope using and microsurgical technique. The lack of lab for microneurosurgery training in low- and middle-income countries like in the environment of this patient is being solved through the university of Wisconsin-Madison microneurosurgery laboratory experience dramatically [22]. This kind of microsurgical and humanitarian project is a great hope for laboratory training availability in these countries [23]. These labs are crucial for the training of young generation of neurosurgeon and for research in skull base approaches and vascular neurosurgery.

Abbreviations

3D	3 Dimensions
CT Scan	Computed Tomography Scan

Conflicts of interest

The authors declare no conflicts of interest.

References

- [1] Sendul SY, Mavi Yildiz A, Yildiz AA. Giant osteomas: Clinical results and surgical approach from ophthalmic point of view. *Eur J Ophthalmol*. 2021; 31(2): 766-773. <https://doi.org/10.1177/1120672120962041>
- [2] Torun MT, Turan F, Tuncel U. Giant ethmoid osteoma originated from the lamina papyracea. *Med Arh*. 2014; 68(3): 209-211. <https://doi.org/10.5455/medarh.2014.68.209-211>
- [3] Wang TH, Ma H, Huang LY, Hung YC, Wang TH, Yu WC, Chiu FY, Wang SJ, Chen WM. Printing a patient-specific instrument guide for skull osteoma management. *J Chin Med Assoc*. 2020; 83(10): 918-922. <https://doi.org/10.1097/jcma.0000000000000364>
- [4] Haddad FS, Haddad GF, Zaatari G. Cranial osteomas: their classification and management. Report on a giant osteoma and review of the literature. *Surg Neurol*. 1997; 48(2): 143-147. [https://doi.org/10.1016/s0090-3019\(96\)00485-5](https://doi.org/10.1016/s0090-3019(96)00485-5)
- [5] Humeniuk-Arasiewicz M, Stryjewska-Makuch G, Janik MA, Kolebac B. Giant fronto-ethmoidal osteoma - selection of an optimal surgical procedure. *Braz J Otorhinolaryngol*. 2018; 84(2): 232-239. <https://doi.org/10.1016/j.bjorl.2017.06.010>
- [6] Mugliston T. A. H, Stafford N. A cranio-facial approach to large osteomas of the fronto-ethmoidal region. *J Laryngol. Otol*. 1985; 99 (10): 979-983. <https://doi.org/10.1017/s0022215100098030>
- [7] Shady J. A, Bland L. I, Kazee A. M, Pilcher W. H. Osteoma of the Fronto-ethmoidal Sinus with Secondary Brain Abscess and Intracranial Mucocoele: Case Report. *Neurosurgery*. 1994 34 (5) 920-923. <https://doi.org/10.1227/00006123-199405000-00024>
- [8] Elwatidy S, Alkhatlan M, Alhumsi T, Kattan A, Al-Faky Y, Alessa, M. Strategy for surgical excision and primary reconstruction of giant frontal sinus osteoma. *Interdisciplinary Neurosurgery: Advanced Techniques and Case Management*. 2021; 23. Article 100905. <https://doi.org/10.1016/j.inat.2020.100905>
- [9] Olumide AA, Fajemisin AA, Adeloye A: Osteoma of the ethmoidal sinus. Case report. *J Neurosurg*. 1975; 42: 343-345. <https://doi.org/10.3171/jns.1975.42.3.0343>
- [10] Lunardi P, Missori P, Di Lorenzo N, Fortuna A. Giant intracranial mucocoele secondary to osteoma of the frontal sinuses: Report of two cases and review of the literature. *Surgical Neurology*. 1993; 39(1): 46-48. [https://doi.org/10.1016/0090-3019\(93\)90109-e](https://doi.org/10.1016/0090-3019(93)90109-e)
- [11] Rappaport J. M, Attia E. L. Pneumocephalus in frontal sinus osteoma: a case report. *J Otolaryngol*. 1994; 23: 430-436.
- [12] Badakere A and Patil-Chhablani P. Orbital apex syndrome: a review. *Eye Brain*. 2019; 11: 63-72. <https://doi.org/10.2147/eb.s180190>
- [13] Cheng KJ, Wang SQ, Lin L. Giant osteomas of the ethmoid and frontal sinuses: clinical characteristics and review of the literature. *Oncol Lett*. 2013; 5: 1724-1730. <https://doi.org/10.3892/ol.2013.1239>
- [14] Blanco Dominguez I, Oteiza Alvarez AV, Martinez Gonzalez LM, Moreno Garcia-Rubio B, Franco Iglesias G, Riba Garcia J. Fronto-ethmoidal osteoma with orbital extension. A case report. *Arch Soc Esp Oftalmol*. 2016; 91: 349-352. <https://doi.org/10.1016/j.oftale.2016.04.002>
- [15] Nagashima H, Aihara H, Tashiro T, Kohmura E. Brain abscess associated with ethmoidal sinus osteoma: a case report. *INAT*. 2014; 1: 97-100. <https://doi.org/10.1016/j.inat.2014.09.004>
- [16] Savastano M, Guarda-Nardini L, Marioni G, Staffieri A. The bicoronal approach for the treatment of a large frontal sinus osteoma. A technical note. *Am J Otolaryngol*. 2007; 28: 427-429. <https://doi.org/10.1016/j.amjoto.2006.10.015>
- [17] Alotaibi N, Hanss J, Benoudiba F, Bobin S, Racy E. Endoscopic removal of large orbito-ethmoidal osteoma in pediatric patient: case report. *Int J Surg Case Rep*. 2013; 4: 1067-1070. <https://doi.org/10.1016/j.ijscr.2013.07.035>
- [18] Oles K, Strek P, Wiatr M, Szaleniec J. Endoscopic treatment of giant skull base osteomas. *Otolaryngol Pol*. 2011; 65: 410-413. [https://doi.org/10.1016/s0030-6657\(11\)70732-6](https://doi.org/10.1016/s0030-6657(11)70732-6)
- [19] Lee DH, Jung SH, Yoon TM, Lee JK, Joo YE, Lim SC. Characteristics of paranasal sinus osteoma and treatment outcomes. *Acta Otolaryngol*. 2015; 135: 602-607. <https://doi.org/10.3109/00016489.2014.1003093>
- [20] Müslüman AM, Oba E, Yilmaz A, Kabukcuoglu F, Uysal E. Giant osteoid osteoma of the ethmoid bone with unusual large nidus. *J Neurosci Rural Pract*. 2012; 3: 383-385. <https://doi.org/10.4103/0976-3147.102637>
- [21] Abou Al-Shaar H, El Arjani T, Timms MS, Al-Otaibi F. Giant orbitoethmoidal osteoma: when an open surgical approach is required. *Case Rep Otolaryngol*. 2015: 872038. <https://doi.org/10.1155/2015/872038> Epub 2015 Mar 23

- [22] Keles A, Cancela AA, Moussalem CK, Kessely YC, Malazonia Z, Shah JM, Gurbuz MS, Gasimov T, Adekanmbi A, Bari MS, Dumot C, Oriola GG, Golidtum JPU, Bin Mohd Nor MA, Omar AH, Ozaydin B, Patel NJ, Dempsey RJ, Baskaya MK. A Novel Approach for Free, Affordable, and Sustainable Microsurgery Laboratory Training for Low- and Middle-Income Countries: University of Wisconsin-Madison Microsurgery Laboratory Experience. *Neurosurgery*. 2024 Jan 30. <https://doi.org/10.1227/neu.0000000000002814>
- [23] Dao I, Kièntoré A, Ouattara O, Bako F, Traoré J, Biogo J, Yameogo SP, Sanou A, Kienou E, Comboigo LJ, Tossou A, Thiombiano A, Taoko L, Lankoande H, Nassoum E, Ouédraogo N, Adéniran SF, Somda A, Zabsonré DS, Kabré A. Periventricular and Intraventricular Tumors in a Low-Income Country: Hard Learning Curve and Outcome of a Young Neurosurgeon from Burkina Faso. *Int J Neurosurg*. 2024; 8(1): 1-10. <https://doi.org/10.11648/j.ijn.20240801.11>