

Treatment of Post-Traumatic Kyphosis of the Spine with Pedicle Subtraction Osteotomy: Case Report

Shuchi Lv, Jianyu Zou, Guowei Zhang, Hua Yang, Zhisheng Ji*, Hongsheng Lin*

Department of Orthopedics, The First Affiliated Hospital of Jinan University, Guangzhou, China

Email address:

zhishengji@jnu.edu.cn (Zhisheng Ji), tlinhsh@jnu.edu.cn (Hongsheng Lin)

*Corresponding author

To cite this article:

Shuchi Lv, Jianyu Zou, Guowei Zhang, Hua Yang, Zhisheng Ji, Hongsheng Lin. Treatment of Post-Traumatic Kyphosis of the Spine with Pedicle Subtraction Osteotomy: Case Report. *International Journal of Neurosurgery*. Vol. 7, No. 2, 2023, pp. 36-40.
doi: 10.11648/j.ijjn.20230702.14

Received: September 11, 2023; Accepted: October 9, 2023; Published: October 31, 2023

Abstract: Kyphosis refers to a deformity in which the spine protrudes abnormally backwards, which involves changes in the anatomical shape of the vertebral body itself and its subsidiary tissues. Kyphosis can cause abnormal appearance, inability to look up and lie down, psychological disturbance, and severe cases can cause dyspnea. We have reported a 40-year-old female patient who was admitted to the hospital due to a 37-year history of kyphosis following a fall. The measurement of preoperative imaging parameters indicated: pelvic incidence (PI) = 40°, pelvic tilt (PT) = 9°, sacral slope (SS) = 31°, lumbar lordosis (LL) = 80°, thoracic kyphosis (TK) = 57°, local kyphosis angle = 137.7°. Based on thorough preoperative planning and discussion, we performed deformed Complex vertebral osteotomy (DCVO). After the surgery, the patient's height was 151cm, which increased by 5cm compared to preoperative height. The postoperative measurements were as follows: pelvic incidence (PI) = 35°, pelvic tilt (PT) = 4.8°, sacral slope (SS) = 40°, lumbar lordosis (LL) = 73°, thoracic kyphosis (TK) = 63°, and local kyphosis angle = 59°. After the operation, the patient recovered well, the treatment effect was satisfactory, and the quality of life was significantly improved. The DCVO technique is a high-risk, demanding procedure that needs to be performed by an experienced spinal surgery team.

Keywords: Kyphosis, Pedicle Subtraction Osteotomy, Deformed Compound Vertebra, Sagittal Balance, Case Report

1. Introduction

Kyphosis refers to a spinal deformity in which the physiological curvature of the spine is abnormally convex backward, which may be caused by trauma, abnormal development, degenerative disc disease, inflammatory disease and infectious disease, and iatrogenic disease [1]. Kyphosis can cause the patient to have an ugly appearance, unable to look up and lie down. Severe deformity can cause chest and abdominal cavity compression, restrict the movement of the diaphragm, significantly reduce lung function, and even lead to psychological disorders. Kyphosis deformity caused by trauma may occur in the cervical, thoracic, thoracolumbar, or lumbar spine, among which the thoracolumbar and lumbar segments are most common, and its severity progresses over time. Generally speaking, when there are complications or neurological deficit, surgical intervention should be

considered [2]. Spinal orthopedic surgery is a high-risk and high-demand surgery [3]. Currently, common orthopedic surgery methods include Smith-Peterson osteotomy (SPO), pedicular subtraction osteotomy (PSO), and vertebral column resection (VCR), etc. Therefore, before surgery, the potential benefits and adverse consequences of various surgical methods must be carefully considered according to the specific conditions of the patient [4], and a personalized treatment plan should be provided.

For patients with severe angular kyphosis due to the fusion of multiple vertebral body deformities into a vertebral complex, some scholars have mentioned a new surgical technique in recent years: deformed Complex vertebral osteotomy (DCVO). A greater range of correction and angulation is achieved by the wedge osteotomy technique performed within the deformed vertebral complex compared to other osteotomies [5]. Through the measurement of preoperative parameters, after adequate preoperative planning

and discussion, we decided to adopt DCVO.

2. Case Presentation

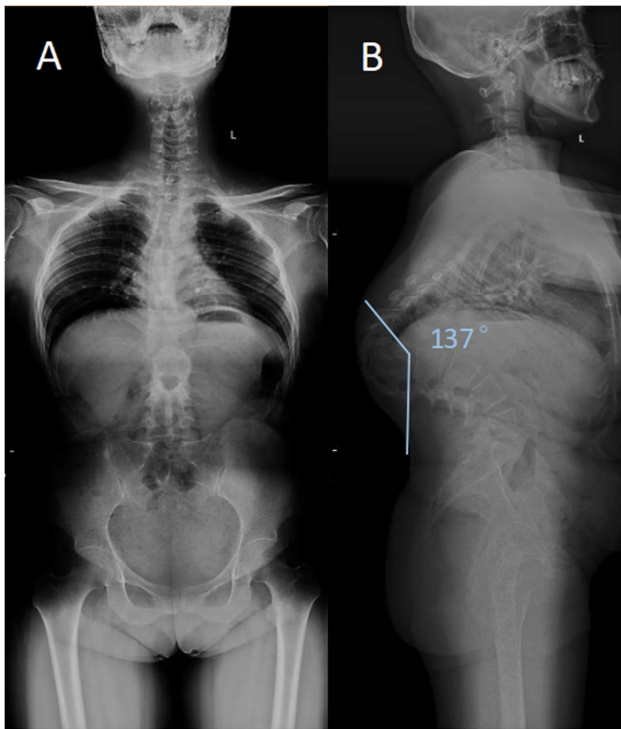


Figure 1. Preoperative X-ray: A full-length coronal X-ray of the spine; B full-length sagittal X-ray of the spine, with a local kyphotic angle of 137°.

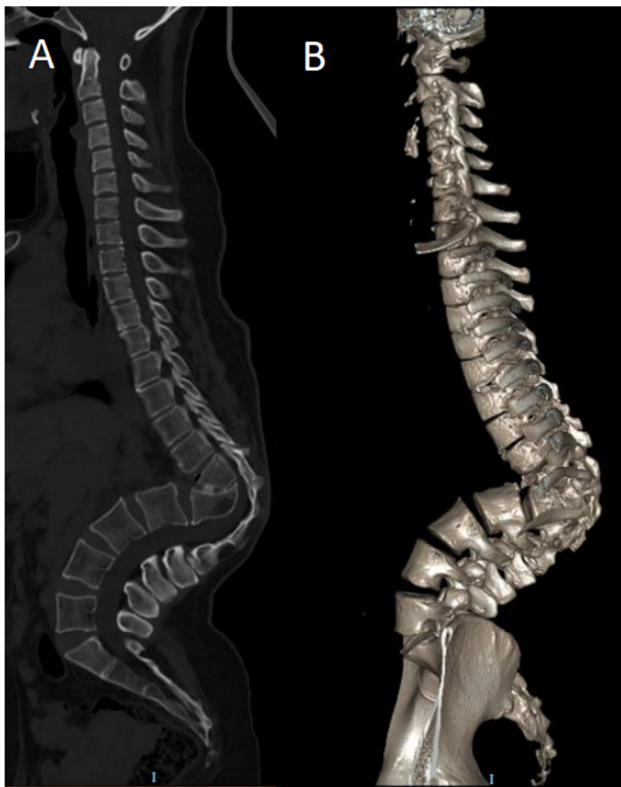

Figure 2. Preoperative CT: A spine CT coronal plane; B spine CT three-dimensional imaging.

A 40-year-old woman came to the First Affiliated Hospital of Jinan University for treatment with severe kyphosis for 37 years. According to the patient's complaint, she gradually developed back kyphosis after an accidental fall when she was 3 years old, and gradually aggravated over time. In the past three years, there have been repeated low back pains, accompanied by shortness of breath after activities, which seriously affect life. Through physical examination, we found that the patient's kyphosis was mainly in the thoracolumbar segment, accompanied by tenderness in the spinous process and paraspinous process of the thoracolumbar segment, and there was no pain in the lower limbs. In addition, the patient's lower limbs felt and moved well, the blood supply was normal, and no abnormalities were found in muscle strength and muscle tension.

Combined with his medical history, physical examination, and imaging examinations including MRI, CT, and X-rays, the patient was diagnosed with kyphoscoliosis caused by trauma. By measurement, the patient's height before operation was 146cm, PI = 40°, PT = 9°, SS = 31°, VAS = 0.8cm, local kyphotic angle = 137.7°.

After perfecting the preoperative preparation, we performed DCVO on the patient. Intraoperative neurophysiological detection of somatosensory evoked potentials (SEP) and motor-evoked potentials (MEP). After general anesthesia, the patient was placed in a prone position with the assistance of a C-arm machine, and a screw was placed at the pedicle of the sixth thoracic vertebra (T6)-fourth lumbar vertebra (L4) through the posterior median approach. During the operation, abnormal fusion of T11, 12 and L1 vertebral bodies can be seen, and only the pedicle and the posterior structure remain. Resect the deformed vertebral body and the rear spinous process, lamina, and facet joints of the adjacent segments, treat the fused vertebral body as a single complex, perform a "V"-shaped osteotomy on the central column, and treat the left vertebral body with an ultrasonic osteotome. The pedicle, such that the outer wall of the pedicle ruptures while the inner wall remains intact. Treat the cancellous bone complex so that the cancellous bone in the center of the vertebral body is close to the upper and lower endplates, and the center is empty. The same method was used to treat the right pedicle. After adequate hemostasis, we excised the posterior lamina to expose the dura. Then, we peeled off the lateral muscles of the left vertebral body, cut off the vertebral body obliquely to the center of the vertebral body at the upper and lower borders of the left side of the complex with a bone knife, and removed the cortical bone. The same method was used to treat the right vertebral body. The nerve root stripper peels off the dura mater and the adhesion behind the vertebral body, and uses an ultrasonic osteotome to break the cortical bone at the back of the vertebral body to remove the cortical bone of the vertebral body. After completing the osteotomy, we processed the bone and soft tissue around the nerve root to avoid compression of the nerve after reduction. Subsequently, the L1 vertebral body and T11 vertebral body were temporarily fixed with short rods. Pre-bending the rods, pre-bending longitudinal connecting rods according to the shape of the die rods. In addition, the

patient's L2-L3 lamina was resected and osteotomized. After the osteotomy angle was confirmed to be about 80° by the C-arm machine during operation, the short rod was removed, the tail of the pedicle screw was inserted crosswise, and the screw was screwed in. After the operating table was reset, the connecting rod was put into the remaining tail of the screw. A large amount of cancellous bone is implanted at the osteotomy plane. Properly and symmetrically pressurize the intervertebral space at the osteotomy in sequence to close the osteotomy plane. After locking the tail cap, it can be seen that the osteotomy angle of the vertebral body is satisfactory and the position of the internal fixation is good.

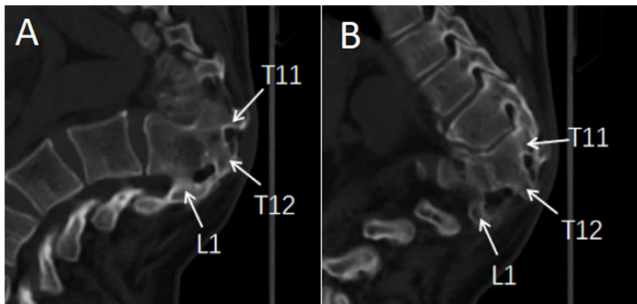


Figure 3. Preoperative CT scan of deformed vertebral pedicles: L1, T11, and T12 vertebral deformities and fusions can be seen on the sagittal plane of spine CT, but the pedicles are intact.

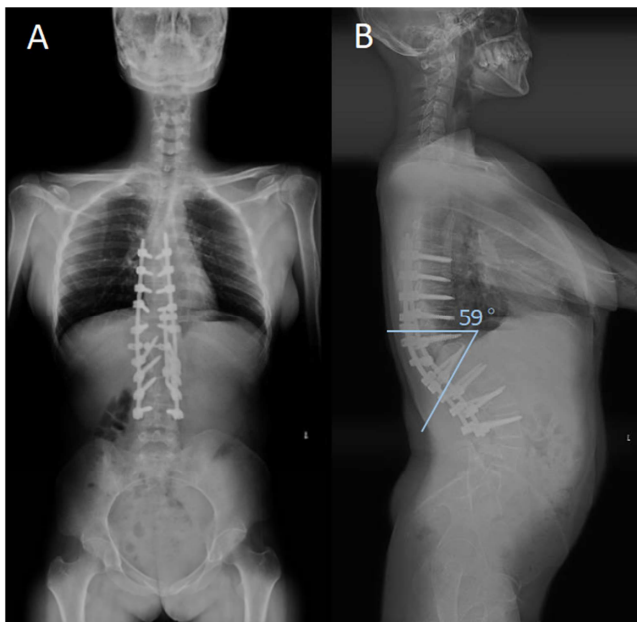


Figure 4. Postoperative X-ray A: Postoperative full-length X-ray coronal plane of the spine; B: Postoperative full-length X-ray sagittal plane of the spine. The local kyphosis angle is 59°, which is 78° better than that before operation.

Postoperatively, patients underwent another imaging and physical examination, including X-rays. We found that the postoperative height of the patient was 151cm, which was 5cm higher than that before the operation. Additional postoperative imaging parameters: PI = 35°, PT = 4.8°, SS = 40°, VAS = 2.5cm, local kyphosis = 59°.

After the operation, the patient felt uncomfortable with

the back pain at the surgical site and the pulling of the abdominal muscles. After bed rest and drug treatment, the symptoms improved significantly. In the 3rd week after operation, the patient went down to the ground after wearing the brace. The patient was followed up regularly in the outpatient clinic after discharge, and he performed well 3 months after the operation, and the pain at the operation site was basically relieved. Follow-up will continue to confirm the integration.

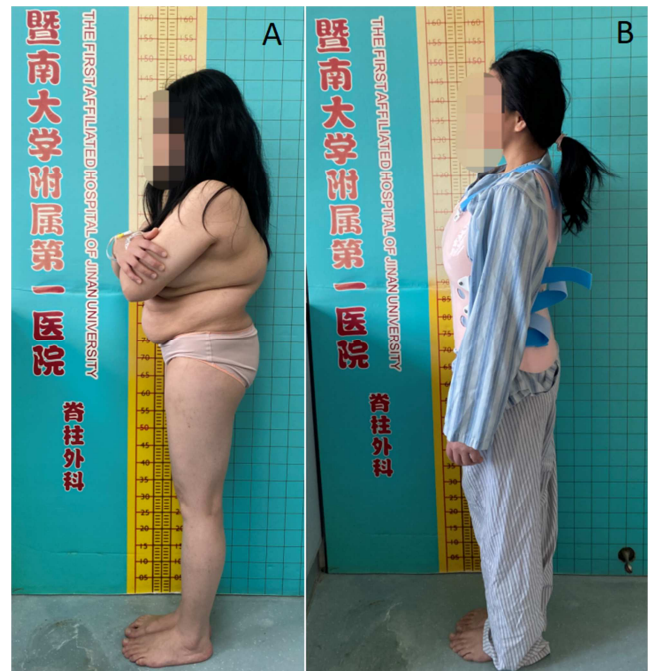


Figure 5. Comparison of preoperative and postoperative appearance: the patient was 146cm before operation, and the patient was 151cm after operation, an increase of 5cm.

3. Discussion

Severe angular kyphosis usually results from neglected or inadequately treated congenital malformation, tuberculosis, trauma, infection, fracture, or extensive laminectomy [4]. If not treated properly, it can lead to disfigurement and even neurological deficits [6]. To restore the sagittal balance of the spine, until now surgical osteotomy has been the first choice for the correction of spinal deformities [7]. However, nerve injury during surgery remains the greatest challenge. In addition, reconstruction of the height of the anterior column, preservation of the nerve roots on both sides of the same vertebral body, and translation of the sagittal plane of the upper and lower vertebrae have always been difficult problems in severe kyphotic surgery [8].

There are many surgical methods for the treatment of kyphoscoliosis. Currently, the more commonly used surgical methods include: SPO, PSO, VCR, etc. Among them, SPO is not suitable as the first-line treatment for angular kyphoscoliosis, because it is difficult to decompress the front of the spinal canal and single-segment SPO only corrects about 10° [9-11]. PSO is to resect the posterior lamina and

pedicle of the spine, and resect the anterior vertebral body in a "V" shape, and then achieve the bony contact of the anterior and middle columns through posterior closure, which can only obtain a correction of 30°-40° [10-12]. VCR requires the removal of one or several entire vertebrae, including adjacent discs and a portion of the ribs in the thoracic region, which can significantly correct severe kyphoscoliosis. However, VCR has several disadvantages, such as neurologic complications, blood loss, operative time, nonunion or pseudoarthrosis, and significantly increased postoperative complication rates [13-15]. The DCVO technique regards multiple deformed vertebral bodies as a complex, and treats complex vertebrae as a whole, which simplifies complex problems. Compared with grade 4 and above osteotomy, DCVO has less trauma, bleeding and operation time, and the apposition of bone to bone also makes fusion more efficient and reduces the risk of pseudarthrosis [5]. For our case, DCVO is more suitable.

Therefore, reasonable preoperative planning is particularly important. It is worth noting that it is far from enough to measure the Cobb angle of kyphosis to determine the osteotomy angle. The two important parameters of local kyphosis angle and sagittal balance are related to the postoperative satisfaction of patients with kyphosis. In addition, it is also necessary to consider the correction of the appearance of the patient. For patients with severe angular kyphoscoliosis, we need to perform osteotomy at the deformed vertebral body, and DCVO is a good choice. However, the main complications of this operation are nerve root injury, cerebrospinal fluid leakage, osteotomy non-fusion, incision infection, and loosening of internal fixation. In our case, the height of the spine was restored by 5 cm and the inferior vena cava was stretched by 5 cm while the thoracic aorta was stretched relatively little.

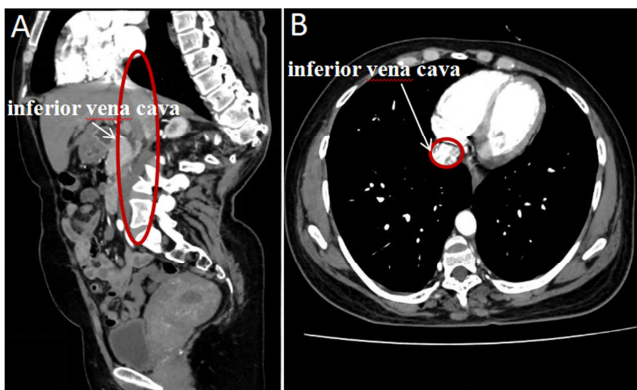


Figure 6. CT shows the inferior vena cava: The inferior vena cava can be seen before operation as being curved due to spinal deformity.

While the spine regains height, the inferior vena cava is stretched and there is a risk of rupture. How much length of the spine will cause the rupture of the inferior vena cava has not been reported in the literature, but it should be taken into account before surgical planning. For patients with malformed vertebral body fusion, the biggest challenge in surgery is the deformity of the pedicle, it is difficult to distinguish the structure of the posterior column of the spine, how to preserve

the bilateral nerve roots of the fused vertebral body, and how to protect multiple pairs of nerve roots during bone-to-bone closure. It has become the most challenging problem in surgery.

4. Conclusion

In conclusion, DCVO is a special osteotomy technique whose effectiveness and safety are an excellent choice to correct severe angular kyphosis and reduce the occurrence of perioperative complications. However, this operation is difficult and requires an experienced spinal surgery team to perform.

References

- [1] YAMAN O, DALBAYRAK S. Kyphosis: Diagnosis, classification and treatment methods [J]. Turkish Neurosurgery, 2014, 24(1).
- [2] BUCHOWSKI J M, KUHNS C A, BRIDWELL K H, et al. Surgical management of posttraumatic thoracolumbar kyphosis [J]. Spine J, 2008, 8(4): 666-77.
- [3] VACCARO A R, SILBER J S. Post-traumatic spinal deformity [J]. Spine (Phila Pa 1976), 2001, 26(24 Suppl): S111-8.
- [4] SONG K S, CHANG B S, YEOM J S, et al. Surgical treatment of severe angular kyphosis with myelopathy: anterior and posterior approach with pedicle screw instrumentation [J]. Spine (Phila Pa 1976), 2008, 33(11): 1229-35.
- [5] ZHANG H Q, XIAO L G, GUO C F, et al. Deformed Complex Vertebral Osteotomy Technique for Management of Severe Congenital Spinal Angular Kyphotic Deformity [J]. Orthop Surg, 2021, 13(3): 1016-25.
- [6] SAR C, ERALP L. Three-stage surgery in the management of severe rigid angular kyphosis [J]. Eur Spine J, 2002, 11(2): 107-14.
- [7] ZHANG H Q, DENG A, GUO C F, et al. Retrospective analysis of deformed complex vertebral osteotomy in children with severe thoracic post-tubercular angular kyphosis [J]. BMC Musculoskelet Disord, 2022, 23(1): 805.
- [8] WANG S, AIKENMU K, ZHANG J, et al. The aim of this retrospective study is to evaluate the efficacy and safety of posterior-only vertebral column resection (PVCR) for the treatment of angular and isolated congenital kyphosis [J]. Eur Spine J, 2017, 26(7): 1817-25.
- [9] BURTON D C. Smith-Petersen osteotomy of the spine [J]. Instr Course Lect, 2006, 55: 577-82.
- [10] CHO K J, BRIDWELL K H, LENKE L G, et al. Comparison of Smith-Petersen versus pedicle subtraction osteotomy for the correction of fixed sagittal imbalance [J]. Spine (Phila Pa 1976), 2005, 30(18): 2030-7; discussion 8.
- [11] HU X, THAPA A J, CAI Z, et al. Comparison of smith-petersen osteotomy, pedicular subtraction osteotomy, and poly-segmental wedge osteotomy in treating rigid thoracolumbar kyphotic deformity in ankylosing spondylitis: a systematic review and meta-analysis [J]. BMC Surg, 2016, 16: 4.

- [12] PARK J S, KIM J, JOO I H, et al. Analysis of risk factors for sagittal translation after pedicle subtraction osteotomy in patients with ankylosing spondylitis [J]. Spine J, 2018, 18(8): 1356-62.
- [13] RILEY M S, LENKE L G, CHAPMAN T M, JR., et al. Clinical and Radiographic Outcomes After Posterior Vertebral Column Resection for Severe Spinal Deformity with Five-Year Follow-up [J]. J Bone Joint Surg Am, 2018, 100(5): 396-405.
- [14] SCHWAB F, BLONDEL B, CHAY E, et al. The comprehensive anatomical spinal osteotomy classification [J]. Neurosurgery, 2014, 74(1): 112-20; discussion 20.
- [15] YANG C, ZHENG Z, LIU H, et al. Posterior vertebral column resection in spinal deformity: a systematic review [J]. Eur Spine J, 2016, 25(8): 2368-75.