

# Percutaneous Ozone Discolysis in the Treatment of Lumboradiculalgia (LBR) by Disc Herniation About a Prospective Study of 298 Cases

Denlewende Sylvain Zabsonre<sup>1</sup>, Wendlassida Joelle Stephanie Tiendrebeogo / Zabsonre<sup>2</sup>, Abdoulaye Sanou<sup>1</sup>, Valentin Bonkougou<sup>1</sup>, Yakouba Haro<sup>1</sup>, Inoussa Zoungana<sup>1</sup>, Fulgence Kabore<sup>2</sup>, Lucie Tiziana Maul<sup>3</sup>, Julie Marie Adeline Wendlamita Kyelem<sup>4</sup>, Boureima Kinda<sup>1</sup>, Abel Kabre<sup>1</sup>

<sup>1</sup>Neurosurgery Department of Yalgado Ouedraogo Teaching Hospital, Ouagadougou, Burkina Faso

<sup>2</sup>Rheumatology Department of Bogodogo Teaching Hospital, Ouagadougou, Burkina Faso

<sup>3</sup>Private Confessional Specialized Hospital of Dorothee Sisters, Alepe, Cote D'Ivoire

<sup>4</sup>Neurology Department of Yalgado Ouedraogo Teaching Hospital, Ouagadougou, Burkina Faso

## Email address:

dzabsonre@gmail.com (Denlewende Sylvain Zabsonre), t\_joelle@gmail.com (Wendlassida Joelle Stephanie Tiendrebeogo / Zabsonre), sanou\_abdou2002@yahoo.fr (Abdoulaye Sanou), bonkvalen@gmail.com (Valentin Bonkougou), yaksterharo@yahoo.fr (Yakouba Haro), zoungranainouss@gmail.com (Inoussa Zoungana), fulgencekabore@yahoo.fr (Fulgence Kabore), srtizianamaule@yahoo.fr (Lucie Tiziana Maule), linejulyk@yahoo.fr (Julie Marie Adeline Wendlamita Kyelem), kindab2@yahoo.fr (Boureima Kinda), kabrel@yahoo.fr (Abel Kabre)

\*Corresponding author

## To cite this article:

Denlewende Sylvain Zabsonre, Wendlassida Joelle Stephanie Tiendrebeogo / Zabsonre, Abdoulaye Sanou, Valentin Bonkougou, Yakouba Haro, Inoussa Zoungana, Fulgence Kabore, Lucie Tiziana Maul, Julie Marie Adeline Wendlamita Kyelem, Boureima Kinda, Abel Kabre. Percutaneous Ozone Discolysis in the Treatment of Lumboradiculalgia (LBR) by Disc Herniation About a Prospective Study of 298 Cases. *International Journal of Neurosurgery*. Vol. 7, No. 1, 2023, pp. 1-6. doi: 10.11648/j.ijn.20230701.11

**Received:** January 23, 2023; **Accepted:** February 21, 2023; **Published:** February 28, 2023

**Abstract:** *Introduction.* Percutaneous ozone discolysis consists of the intradiscal injection of medical ozone for therapeutic purposes. This is an innovative per cutaneous surgical treatment of which the use is recent in our department. The purpose of this work was to report our experience on this practice in our country where the neurosurgeon is the first and only recourse in case of disc LBR with failure of conservative treatment. *Methods.* This was a retrospective study from 2016-2021, including all consenting patients in whom the diagnosis of disc LBR with failure of conservative treatment was retained and who benefited from ozone discolysis. These patients were reassessed (VAS, Lasegue sign and neurological examination) at one week, two weeks, one month, three months. *Results.* Lumbar ozone discolysis was performed in 298 patients or 84.4% of lumbar disc herniation surgeries. This discolysis indication was mainly disabling LBR (68.8%) and hyperalgetic LBR (24.8%). Discolysis concerned 1 level (48.0%); 2 levels (43.3%) and 3 levels (8.7%). At 1 week, 2 weeks, 1 month and 3 months there were respectively 61.1%; 79.2%; 90.3% and 93.6% asymptomatic cases. Pending conventional surgery, discolysis was performed in 19 cases (6.4%) of paralyzing LBR resulting in total recovery. No complications were noted. *Conclusion.* Ozone discolysis was currently the most commonly used treatment for the management of disc LBR after failure of conservative treatment. Patients' favorable clinical evolution in the short and medium term indicates the efficacy of the treatment.

**Keywords:** Disc Herniation, Ozone Therapy, Percutaneous Surgery, Lumboradiculalgia

## 1. Introduction

Lumboradiculalgia (LBR) is very common, especially in active adults. It is one of the most common health problems in

industrialized and non-industrialized countries [1]. CT scan is usually enough to link this pain to its disc origin. Magnetic Resonance Imaging (MRI) is only useful in case of doubts on CT scans.

Treatment is primarily conservative. Surgery is only indicated in around 10-20% of cases where this conservative treatment has failed (disabling LBR, hyperalgesic LBR) or in the event of paralyzing LBR [1-3].

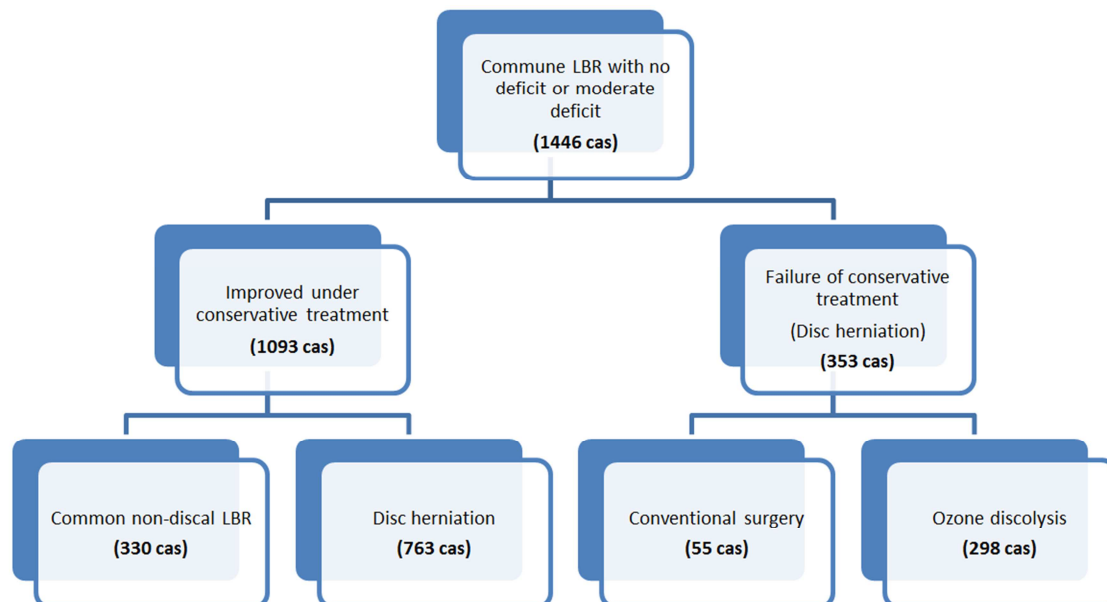
Many surgical procedures (conventional discectomy, minimally invasive microscopic or endoscopic surgery, percutaneous surgery) are offered if conservative treatment fails [4]. Percutaneous surgery seems to have the best benefits for the patient when the product used is little or no harmful to the patient [5]. Nowadays, ozone discolysis (or chemonucleolysis or nucleolysis or Intradiscal ozone therapy) is one of the emerging treatments because of the total ozone safety at therapeutic doses [6]. This treatment consists of an intradiscal injection, according to various protocols, a mixture of oxygen and ozone (medical ozone or oxygen-ozone=O<sub>2</sub>-O<sub>3</sub>). It can be repeated several times in case of recurrence. At present, there are still no standardized procedures for this purpose [7].

In West Africa, conventional open surgery was the main treatment performed in this spine pathology. In Burkina Faso, since July 2016, percutaneous ozone discolysis is practiced. The aim of this work was to report our experience on this practice in our country where neurosurgeon is the first and only recourse in case of disc LBR with conservative treatment failure.

## 2. Method

This was a prospective study, run over a period of five years from 1 July 2016 to 30 June 2021 in Yalgado Ouedraogo Teaching Hospital neurosurgery department in Ouagadougou, Burkina Faso.

The study population was patients who had admitted for a common LBR without neurological deficits or with a moderate deficit (paresis with muscle strength  $\geq 3/5$  or uni radicular plegia with muscle strength  $< 3/5$ ). Were included in the study, all patients in whom the diagnosis of disc LBR with failure of conservative treatment (drug and physical treatment) had been retained and who benefited from lumbar discolysis with ozone after giving their enlightened consent. Were not included any case of common LBR effectively treated conservatively, all cases of non-discal common LBR, any case of discal LBR after failure of conservative treatment with appearance of a significant neurological deficit (multi-root plegia with muscular strength  $< 3/5$ ). Conventional surgery had been proposed to these cases of common LBR with a significant deficit. Were therefore recorded 1446 cases of common LBR without deficit or with a moderate neurological deficit. Among them 1093 were improved by the conservative treatment and in 353 cases, there was a failure of the conservative treatment. Among these cases of failure of the conservative treatment, a conventional discectomy had been performed in 55 patients who presented during the conservative treatment a significant neurological deficit. Percutaneous discolysis with ozone was performed in 298 patients who had disc LBR without neurological deficits or with moderate deficit and with failure of conservative treatment. All these 298 patients were included in our study. These patients had not previously benefited from percutaneous discolysis with ozone because this technique is recent in our country and it is the first study that we are carrying out on this subject. Figure 1 shows the flowchart of common LBR cases without neurological deficits or with moderate deficit supported in our department.

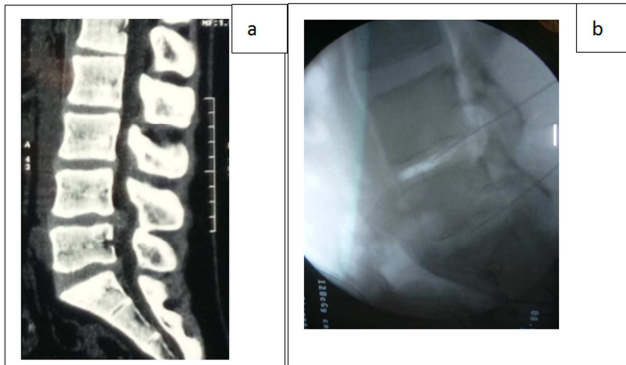


**Figure 1.** Diagram of flow of common LBR cases without neurological deficits or with moderate deficit supported in the department.

Concerning percutaneous ozone discolysis procedure; in all patients; discolysis was done on an outpatient basis, under local anesthesia in the operating room with strict compliance

with asepsis. Patient is installed in ventral decubitus on 2 blocks (shoulders and iliac crests), fluoroscopic identification of the disc to be treated, local infiltration of lidocaine,

sometimes associated with sedation and intravenous analgesia. The lumbar entry point corresponds to a line in the sagittal plane passing through the outer edge of the lumbar muscle masses (approximately 10 cm outside spines line). A special fine and long discolysis needle is implanted in the disc and then between 50 and 150 cubic millimeter of an oxygen-ozone mixture ( $O_2-O_3$ ) is injected whose concentration of ozone in this mixture varies between 20 and 25 micrograms per cubic millimeter. Figure 2 shows images (CT and per-procedural fluoroscopy) of a case of lumbar discolysis.



**Figure 2.** Images of a case of lumbar ozone discolysis. (a) Pre-procedural parenchymal window and sagittal reconstruction CT scan showing L4L5 and L5S1 disc herniations. (b) per procedural fluoroscopy showing discolysis needles implanted in L4L5 and L5S1 with the presence of ozone in L4L5 in the form of a more visible opacity in L4L5.

Thirty minutes to an hour after discolysis patient is allowed to go home. Subsequently, these patients were reassessed on visual analogic scale (VAS), Lasegue sign and neurological at one week, two weeks, one month, three months. Regarding visual analogic scale (VAS), there was no pain (VAS = 0 cm). Pain was mild (VAS = 1-2 cm); moderate (VAS = 3-4 cm); intense (VAS = 5-7 cm) or very intense (VAS = 8-10 cm). Lasegue sign was absent when the angle was less than 70°. Pain was mild (50°-70°), moderate (30°-50°), intense (10°-30°) or very intense (<10°). There was no motor deficit when muscle strength (MS) was rated at 5/5. There was paresis (MS ≥3/5) or plegia (MS < 3/5).

### 3. Results

#### 3.1. Frequency and Socio-Demographic Data

During the 5-year study period, 298 cases of percutaneous lumbar ozone discolysis were performed. Percutaneous lumbar discolysis with ozone represented 84.4% of surgical procedures performed in the cases of conservative treatment failure in the presence of a disc LBR with no deficit or with a moderate deficit.

Patients mean age was 50.3 years with a standard deviation of 12.1. Extremes were 14 and 84 years. Sex ratio was 0.9 (144 male/154 female).

#### 3.2. Diagnostic Data

The average time between the first symptom and the first

consultation in our department was 33.8 months with extremes of 3 days and 20 years. All patients had received prior drug therapy, including 219 cases (73.5%) per os, 72 cases (24.2%) parenteral and 20 cases (6.7%) epidural corticosteroid infiltration. These were paracetamol (291 cases or 97.6%); nonsteroidal anti-inflammatory drugs (161 cases or 54%); tramadol (161 cases or 54%); paracetamol codeine (154 cases or 51.7%); corticosteroids (134 cases or 4.5%); muscle relaxants (85 cases or 28.5 %); morphine (7 cases or 2.4%).

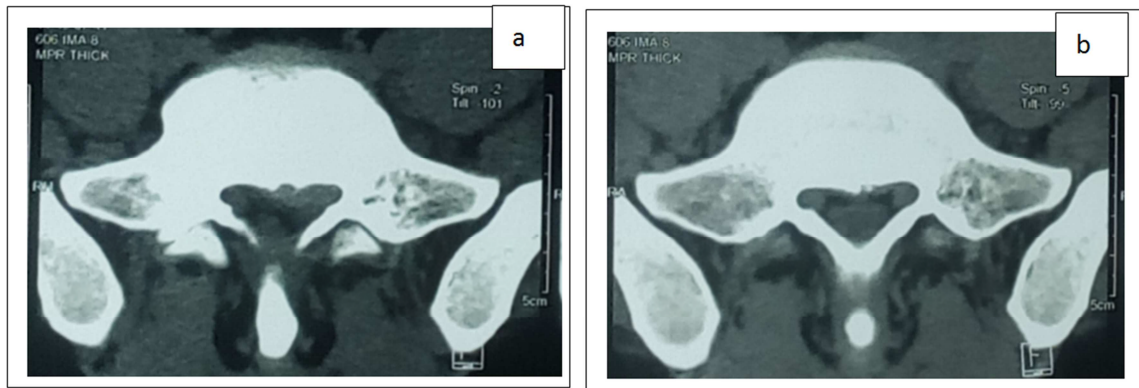
No pathological history was noted in 137 patients (46%). In the other patients, history was as follows high blood pressure (42 cases or 14.1%), peptic ulcer disease (25 cases or 8.4%), degenerative lumbar spine surgery (16 cases or 5.4%), overweight or obesity without quantification (23 cases or 7.7%), diabetes (15 cases or 5%), hepatitis B (1 case or 0.3%), mitral insufficiency (1 case or 0.3%), acute pericarditis (1 case or 0.3%). None of the patients had a history of lumbar ozone discolysis.

The functional signs were represented by LBR (270 cases or 90.6%); low back pain (12 cases or 4%); functional impotence (6 cases or 2%); claudication (5 cases or 1.7%); paresthesia (2 cases or 0.7%). According to the visual analogic scale (VAS); pain was mild (VAS 1-2) in 153 cases (51.3%); moderate (3-4) in 10 cases (3.4%); intense (VAS 5-7) in 61 cases (20.5%); very intense (VAS 8-10) in 74 cases (24.8%).

On physical examination, there was no sign of Lasegue in 150 cases (50.3%). Lasegue sign was present with an angle of less than 10° in 74 cases (24.8%); 11-30° in 12 cases (4%); 31-50° in 46 cases (15.4%) and 51-70 in 16 cases (5.4%). Root involvement was right unilateral in 112 cases (37.6%); left unilaterally in 94 cases (31.5%) and bilateral in 92 cases (30.9%). It was well systematized following a root tract in 190 cases (63.8%) and badly systematized in the other cases. For systematized attacks, L4 root was involved in 11 cases (5.8%); L5 in 76 cases (40%); S1 in 67 cases (35.3%); L5 and S1 roots in 26 cases (13.7%); L5 and L4 in 10 cases (5.3). Root motor disorders were noted in 59 patients (19.8%) including 40 cases of paresis (13.4%) and 19 cases of uniradicular plegia (6.4%). Root hypoesthesia was present in 28 patients (9.4%).

All patients performed at least one imaging exam each. CT scan was performed by 250 patients (83.9%); MRI by 35 patients (11.7%); CT scan + standard X-ray by 8 patients (2.7%); CT scan+ MRI by 3 patients (1%); CT scan + MRI + standard X-ray by 1 patient (0.3%) and CT scan + MRI+ saccoradiculography-CT by 1 patient (0.3). In total it was performed 263 CT (88.3%), 39 MRI (13.1%), 9 standard X-rays (3%) and 1 saccoradiculography-CT (0.3%). Herniated disc involved at 1 level in 143 cases (48.0%); 2 levels in 129 cases (43.3%) and 3 levels in 26 cases (8.7%). It sat in L4L5 in 224 cases (75.2%); in L5S1 in 221 cases (74.2%); in L3L4 in 95 cases (31.9%) and in L2L3 in 20 cases (6.7%).

Three control CT scans were performed 3 months after ozone discolysis. It made it possible to objectify a reduction of hernia in 1 case and a stable aspect of hernia in the other 2 cases. Figure 3 shows pre-and post-procedural images of patients in whom there was a frank reduction of the hernia after 3 months ozone discolysis.



**Figure 3.** Pre-and post-procedural images of a patient in whom there was a frank reduction of the hernia after 3 months ozone discolysis. (a): pre-procedural images showing a left postero-lateral disc herniation completely filling the left lateral recess that the root is not visible. (b): post-procedural image showing the free left lateral recess with the root clearly visible.

### 3.3. Therapeutic and Evolutive Data

It was after the failure of conservative treatment that discolysis was indicated in cases of non-paralyzing LBR (279 cases, i.e., 93.6%); in 19 cases (6.4%) it was paralyzing LBR. Among non-paralyzing LBR there was disabling LBR in 205 cases, i.e., 68.8% (including 165 non-deficient cases and 40 cases of paresis) and hyperalgesic LBR in 74 cases (24.8%). In the same patient, the number of discs levels treated by discolysis and the site of discolysis were the same as those

discs' herniation objectified on medical imaging. No complications related to this procedure were noted.

One week after discolysis, 182 patients (61.1%) showed no pain (VAS = 0) and had a normal physical examination. There was no Lasegue sign in 211 cases (70.8%). A regression of motor deficits was noted in all cases. At 2 weeks, 1 month and 3 months, there were respectively 236 (79.2%); 269 (90.3%) and 279 (93.6%) asymptomatic cases (absence of pain and deficit). Table 1 summarizes the evolution of the VAS, Lasegue sign and the radicular motor deficit of patients.

**Table 1.** Evolution of VAS, Lasegue sign and root motor deficit of patients after ozone discolysis.

	Pre-discolysis		Post discolysis							
	n	%	1 week	%	2 weeks	%	1 month	%	3 months	%
Analogue visual scale (VAS))										
No pain (VAS = 0 cm)	0	0.0	182	61.1	236	79.2	269	90.3	279	93.6
Mild pain (VAS = 1-2 cm)	153	51.3	101	33.9	51	17.1	17	5.7	10	29.4
Moderate pain (VAS = 3-4 cm)	10	3.4	9	3.0	6	2.0	6	2.0	9	26.5
Severe pain (VAS = 5-7 cm)	61	20.5	6	2.0	5	1.7	6	2.0	0	0.0
Very severe pain (VAS = 8-10 cm)	74	24.8	0	0.0	0	0.0	0	0.0	0	0.0
Lasegue sign										
No Lasegue sign (>70°)	150	50.3	211	70.8	247	82.9	276	92.6	293	98.3
Pain was mild (50°-70°)	16	5.4	76	25.5	51	17.1	22	7.4	5	1.7
Moderate pain (30°-50°)	46	15.4	11	3.7	0	0.0	0	0.0	0	0.0
Severe pain (10°-30°)	12	4.0	0	0.0	0	0.0	0	0.0	0	0.0
Very severe pain (<10°)	74	24.8	0	0.0	0	0.0	0	0.0	0	0.0
Root motor deficits	59	19.8	29	9.7	6	2.0	0	0.0	0	0.0
Root paresis	40	13.4	21	7.0	6	2.0	0	0.0	0	0.0
Root plegia	19	6.4	8	2.7	0	0.0	0	0.0	0	0.0

## 4. Discussion

Lumbar ozone discolysis accounted for more than 3/4 of surgical activity for LBR by disc herniation with a surgical indication (LBR with conservative treatment failure). This high prevalence of lumbar ozone discolysis could be explained by the many advantages offered by this treatment. Indeed, it has the advantage not only its lower cost, but also, the harmlessness of ozone, the fact that it is performed on an outpatient basis, the fact that it better respects the anatomy,

because no resection is necessary so no spinal instability aggravated or caused by this gesture and especially the fact that it can be easily resumed in case of recurrence. In addition, no complications of ozone discolysis were noted by most authors [8-12]. For other authors, it is a cost-effective procedure with a very low complication rate (0.1%) [13]. Radicular pain is resolved before back pain, as seen with microdiscectomy. Meta-analyses from large patient samples have demonstrated that ozone discolysis procedure is safe and effective in the short and long term, with recognized benefits up to 10 years after treatment [13].



Microendoscopic discectomy is less invasive than conventional open discectomy, but the long-term benefits of this technique are still debated. Furthermore, after surgery, in up to 40% of cases, patients develop worsening pain and failure syndrome of back surgery, which is an important cause of chronic pain with high morbidity and disability [14]. Thus, several percutaneous techniques of injection Intra discs have been proposed: cortisone, ozone, ethanol gel, Platelet-Rich Plasma (PRP) injections, mixture of platelet concentrates and growth factors [5]. All these percutaneous techniques have their advantages and disadvantages. Nucleolysis (or discolysis) of papain once used has been abandoned because of its complications. [15]. Similarly, sometimes serious complications have been reported concerning steroids: root damage, formation of medullary or epidural hematomas, abscesses [16]. In addition, several studies demonstrate the advantages of ozone discolysis compared to conventional surgery, microsurgery and other percutaneous techniques [17]. Regarding the cost benefits of ozone discolysis, authors had noted that compared to the conventional surgery group, the ozone group showed: 1) a significantly lower number of days of hospital stay: median of 3 days,  $p = 0.012$ ; 2) significantly lower costs: Median EUR 3702 versus EUR 364,  $p = 0.029$  [17].

In our study, the indication of ozone discolysis was a disabling (68.8%), hyperalgetic (24.8%) or paralyzing (6.4%) LBR. CT scan was performed in 88.3% of cases; MRI in 13.1%. CT scan was sufficient to make the decision of ozone discolysis. It has the advantage of detecting calcified hernias causes of failure of ozone discolysis. Paralyzing LBR is not one of the classic indications for ozone discolysis. It was imposed on us by the financial conditions of patients that did not allow to honor medical expenses of conventional surgery. So, we performed ozone discolysis while waiting for surgery. Fortunately, this gesture had led to a recovery of the motor deficits. Ozone discolysis has also been proposed (in 9.06% of cases) in our series when certain patient histories (mitral insufficiency, acute pericarditis, hypertension, UGD...) constituted limits to prolonged prescription of certain drugs or to realization of general anesthesia. This has also been the case for other authors [18].

In our study, after ozone discolysis, an absence of symptoms and signs was found in 61.1% of patients at one week; 79.2% at two weeks; 90.3% at one month and 93.6% at three months. Similar good results have been published [9, 10, 19, 20]. The reduction in VAS score between study baseline and study end (12 months) was 7.68 to 2.17 [20]. At 2 months there was a significant decrease in pain disability in 37 patients (74%) which increased minimally at 6 months 38 patients (76%) ( $P < 0.001$  and 99.9% CI [21]. These results were also very satisfactory for deficits. Thus, after 2 weeks, out of a series of 13 patients; Eleven reported complete disappearance of their pain and 12 had a complete recovery of their paresis [19]. At 1 month the complete recovery of deficit increased to 13/13 while the results remained unchanged for pain which underlines the subjective nature of pain (VAS) [19]. VAS subjectivity could explain why in our series why results

were better for Lasague sign than for VAS. Ozone discolysis effectiveness has also been noted in cases of recurrence following conventional surgery [14, 22]. After ozone discolysis, clinical improvement can be done gradually over about 6 months even without a repeat of the procedure [19, 20, 23]. This result was unchanged after a new ozone discolysis [5]. Concentrations ranged from 25 to 40  $\mu\text{g/ml}$  of  $\text{O}_3\text{-O}_2$  for volumes ranging from 5 to 10 ml and the combination of steroids did not cause any static difference in clinical results [21, 24]. We used a concentration of 20–25  $\mu\text{g/ml}$  of  $\text{O}_3\text{-O}_2$  but with a much larger volume (50-150 ml) without noting any particular incident. On the other hand, the importance of injected volume contributed to reinforce mechanical effect of ozone discolysis.

A single CT scan of control on the three carried out in our series had made it possible to objectify a frank reduction in the size of the hernia. Other authors [11, 21, 24, 25] performed a control MRI to objectify a reduction of the hernia. Multiple linear regression analysis showed a strong correlation between percentage change in post-treatment herniated disc volume and the volume of the herniated disc before treatment and the VAS before treatment ( $p < 0.05$ ) [25]. In our series in the 2 cases where the control CT scan showed a stable aspect of the hernia, patients still reported an improvement in their pain. This allows us to suspect that a control MRI done in an appropriate way would have allowed us to objectify it is only a discrete regression of the hernia size. It seems that its efficacy in treating low back pain associated with disc herniation comes from multiple properties together: (1) the biochemical cascade of the arachidonic acid into inflammatory prostaglandins is directly interrupted by ozone; (2) it increases the concentration of oxygen in tissues suffering from hypoxemia, due to the reduced microcapillary blood flow determined by the mechanical disc compression; (3) fibroblastic cells activity is stimulated by ozone to repair the damaged disc by deposition of collagen; and (4) most important, it reduces the disc volume acting directly on the nucleus pulposus because it breaks the glycosaminoglycan chains and prevents water retention, resulting in dehydration of the disc [13]. Ant inflammatory activities, tissue oxygenation, repairing processes, and disc shrinking: all these factors contribute to relieve low back pain few after the procedure [13]. To these biochemical effects, we note a mechanical effect because the injection of ozone increases disc space with the opening of the foramina and reduced root compression. This mechanical effect most often contributes to immediate postoperative analgesia.

## 5. Conclusion

Percutaneous lumbar ozone discolysis was by far the most frequently performed surgery for failure of conservative treatment. Its indications were dominated by disabling or hyperalgetic LBR.

CT scan was the most frequently used in medical imaging. It had revealed the herniated disc in all cases. L4-L5 and L5-S1 discs were the most affected.

Results of ozone discolysis were very satisfactory in almost all cases with no complications noted. It is a beneficial treatment for both patient and surgeon with its economic, social and anatomical advantages.

## Conflict of Interest

All the authors do not have any possible conflicts of interest.

## References

- [1] Marco-Vincenzo C, Enrico T, Oliver P, Karl S. Hernie discale lombaire – Diagnostic et prise en charge. *Rev Med Suisse* 2014; 10 (454): 2376-82.
- [2] Corniola MV, Tessitore E, Gautschi OP, Schaller K.. Hernie discale lombaire – Diagnostic et prise en charge. *Rev Med Suisse*. 2014; 10 (454): 2376-82.
- [3] Deyo RA, Mirza SK. Herniated Lumbar Intervertebral Disk. *New England Journal of Medicine*. 2016; 374 (18): 1763-72.
- [4] Wu PH, Hyeun Sung Kim HS, Jang IT. Intervertebral Disc Diseases PART 2: A Review of the Current Diagnostic and Treatment Strategies for Intervertebral Disc Disease. *Int J Mol Sci*. 2020 20; 21 (6): 2135.
- [5] Gouze H, Rozenberg S. Intradiscal injections: update about different techniques and indications. *La Lettre du Rhumatologue*. 2014; 440: 8-37.
- [6] Hassen-Khodja R, Lepant L. Ozonothérapie dans le traitement des atteintes musculosquelettiques d'origine spinale. Direction de l'évaluation des technologies et des modes d'intervention en santé (DETMIS) du Centre hospitalier de l'Université de Montréal (CHUM). 2012.
- [7] Migliore A, Sorbino A, Bacciu S, Bellelli A, Frediani B, Tormenta S and al. The Technique of Intradiscal Injection: A Narrative Review. *Ther Clin Risk Manag*. 20209; 16: 953-968.
- [8] Costa T, Linhares D, Ribeiro da Silva M, Neves N. Ozone therapy for low back pain. A systematic review. *Acta reumatol port*. 2018; 43: 172-181.
- [9] Hosseini B, Taheri M, Sheibani K. Comparing the results of intradiscal ozone injection to treat different types of intervertebral disc herniation based on MSU classification. *Interventional Neuroradiology*. 2018; 25 (1): 111-116.
- [10] Magalhaes FNDO, Dotta L, Sasse A, Teixeira MJ, Fonoff ET. Ozone therapy as a treatment for low back pain secondary to herniated disc: a systematic review and meta-analysis of randomized controlled trials. *Pain Physician*. 2012; 15 (2): E115-29.
- [11] Simon C. Efficacité du traitement par Ozonothérapie : aspects cliniques et radiologiques. dumas-02090867. 2018; 78.
- [12] Murphy K, Muto M, Steppan J, Meaders T, Boxley C. Treatment of Contained Herniated Lumbar Discs With Ozone and Corticosteroid: A Pilot Clinical Study. *Canadian Association of Radiologists Journal*. 2015; (66): 377-384.
- [13] Giurazza F, Guarnieri G, Murphy KJ, Muto M. Intradiscal O2O3: Rationale, Injection Technique, Short- and Long-term Outcomes for the Treatment of Low Back Pain Due to Disc Herniation. *Canadian Association of Radiologists Journal*. 2017; 68: 171-177.
- [14] Barbosa DC, Dos Ângelos JS, Josino de Macena GM, Magalhães FNO, Fonoff ET. Effects of ozone on the pain and disability in patients with failed back surgery syndrome. *Rev Assoc Med Bras*. 2017; 63 (4): 355-360.
- [15] Runge M. La chimionucléolyse Ann. *Kinésithér*. 1987; 14 (09): 431-43.
- [16] Federico B, Smaldone F, Varrassi M, Arrigoni F, Barile A, Di Cesare E and al. MRI findings in lumbar spine following O2–O3 chemiodiscolysis: A long-term follow-up. *Interventional Neuroradiology*. 2017; 23 (4): 444-450.
- [17] Clavo B, Robaina F, Urrutia G, Bisshopp S, Ramallo Y, Szolna A and al. Ozone therapy versus surgery for lumbar disc herniation: A randomized double-blind controlled trial. *Complementary Therapies in Medicine*. 2021; 59: 1-5. 102724.
- [18] Bonetti M, Fontana A, Martinelli F, Andreula C. Oxygen-ozone therapy for degenerative spine disease in the elderly: a prospective study. *Acta Neurochir*. 2011; 137-42.
- [19] Dall'olio M, Princiotta C, Cirillo L, Budai C, De Santis F, Bartolini S and al. Oxygen-Ozone Therapy for Herniated Lumbar Disc in Patients with Subacute Partial Motor Weakness Due to Nerve Root Compression. *Interventional Neuroradiology*. 2014; 20: 547-554.
- [20] Zhang Y, Ma Y, Jiang J, Ding T, Wang J. Treatment of the lumbar disc herniation with intradiscal and intraforaminal injection of oxygen-ozone. *J Back Musculoskelet Rehabil*.. 2013; 26 (3): 317-22.
- [21] Ezeldin M, Leonardi M; Princiotta C, Dall'olio M, Tharwat M, Zaki M and al. Percutaneous ozone nucleolysis for lumbar disc herniation. *Neuroradiology*. 2018; 60: 1231–1241.
- [22] Kılıç M, Erçalık T. The Effect of Lumbar Spinal Surgery History on Intradiscal O2–O3 Treatment Results in Patients with Lumbar Disk Herniation. *Med Bull Sisli Etfal Hosp* 2019; 53 (2): 148–153.
- [23] Ghatge S, Modi PD, Modi DB, Clinical and Radiological Improvement Following Ozone Disc Nucleolysis: A Case Report *Cureus* 2017 13; 9 (4): e1162.
- [24] Elawamy A, Kamel EZ, Hassanien M, Wahba OM, Amin SE. Implication of Two Different Doses of Intradiscal Ozone-Oxygen Injection upon the Pain Alleviation in Patients with Low Back Pain: A Randomized, Single-Blind Study. *Pain Physician*. 2018; 21 (1): E25-E31.
- [25] Negro A, Paolucci A, Russo C, Di Stasi M, Guerriero P, Arrigoni F and al Predictive factors of volumetric reduction in lumbar disc herniation treated by O2-O3 chemiodiscolysis. *Acta Biomed*. 2020. 13; 91 (8-S): 89-97.