

## Case Report

# Thoracic Spinal Arachnoid Cyst Causing Neuropathic Arthropathy of the Elbow

Adam Alayli<sup>1,4</sup>, Jonah Gordon<sup>1,4</sup>, Khaled Abdelghany<sup>1,4</sup>, Gavin Lockard<sup>1,4</sup>, Anthony Urbisci<sup>3</sup>, Gautam Rao<sup>2</sup>, Nam Tran<sup>2,4,\*</sup>

<sup>1</sup>College of Medicine, University of South Florida Morsani, Tampa, United States

<sup>2</sup>Department of Neurosurgery, University of South Florida, Tampa, United States

<sup>3</sup>Department of Physical Medicine and Rehabilitation, James A. Haley Veterans Hospital, University of Florida, Tampa, United States

<sup>4</sup>Department of Neuro-Oncology, Moffitt Cancer Center and Research Institute, Tampa, United States

## Email address:

[nam.tran@moffitt.org](mailto:nam.tran@moffitt.org) (Nam Tran)

\*Corresponding author

## To cite this article:

Adam Alayli, Jonah Gordon, Khaled Abdelghany, Gavin Lockard, Anthony Urbisci, Gautam Rao, Nam Tran. Thoracic Spinal Arachnoid Cyst Causing Neuropathic Arthropathy of the Elbow. *International Journal of Neurosurgery*. Vol. 6, No. 2, 2022, pp. 48-51.

doi: 10.11648/j.ijn.20220602.14

Received: August 19, 2022; Accepted: September 13, 2022; Published: September 27, 2022

**Abstract:** Neuropathic arthropathy (NA), or Charcot arthropathy, involves rapid degeneration and instability of a joint caused by hypesthesia. This condition is commonly caused by diabetes, while syringomyelia and arachnoid granulations are rare causes of NA. We report a 50-year old male who presents with progressive numbness to his arms, weakness to his right hand and mass to the right elbow. A diagnosis of neuropathic arthropathy of the elbow was made after MRI of the cervical and thoracic spine revealed a compressive thoracic arachnoid granulation causing cervical syringomyelia. We highlight the importance of a thorough workup including key imaging characteristics that resulted in the diagnosis. Thoracic surgical decompression successfully restored CSF flow and reduced the cervical syringomyelia. The patient remained neurologically stable at the most recent follow-up, although no known treatment halts disease progression once NA has developed.

**Keywords:** Neuropathic Arthropathy, Charcot Joint, Arachnoid Cyst, Syringomyelia

## 1. Introduction

In 1968 Jean-Martin Charcot described the features of neuropathic arthropathy (NA) seen in advanced syphilis. Later named Charcot's joint, NA refers to the progressive degeneration and instability of a joint caused by hypesthesia due to nerve damage. The primary complaint is painless joint swelling and exam shows warmth leading to suspicion of infection or trauma [1]. Although NA is commonly associated with diabetes [2], it can result from syringomyelia, primarily in the upper extremity [3]. Nontraumatic causes of syringomyelia include Chiari type 1 malformation, basilar invagination, intramedullary spinal cord tumors, and arachnoid cysts [4]. The key to successful diagnosis is a thorough history, exam, and workup to rule out mimicking

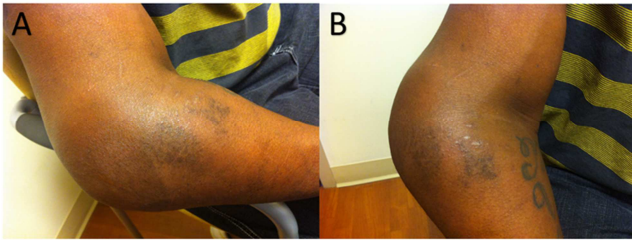
pathologies such as peripheral neuropathies [1]. We present a rare case of NA of the elbow resulting from syringomyelia attributed to arachnoid granulation tissue.

## 2. Case Report

A 50-year-old male presented to the emergency room with symptoms of progressive painless right elbow swelling over 2 months and hearing a 'crunch' with elbow movement. He complains of numbness to his arms and weakness to his right hand. He denied additional symptoms, trauma, diabetes, chronic disease, or extramarital sex. He was referred to our tertiary cancer center for evaluation of a possible malignant neoplasm.

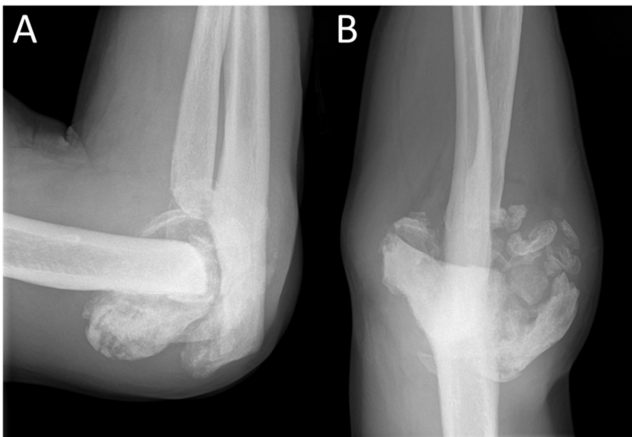On presentation, he was afebrile, well-developed, and in no acute distress. He had diminished sensation to light touch and

pinprick to both arms. Focused right elbow exam revealed a circumferentially swollen joint, extending 5 centimeters proximally and distally (Figure 1A & 1B). The swelling was mostly around the lateral aspect and felt slightly warm without erythema or tenderness. He demonstrated full passive elbow flexion and extension without pain. Crepitus was noted during range of motion. Supination and pronation were intact, though diminished. Diminished sensation to light touch and pinprick was noted in both upper extremities from mid-humerus and extending distally. He had 4/5 right hand intrinsic weakness.



**Figure 1.** Lateral (A) and AP view of right elbow showing marked swelling without erythema.

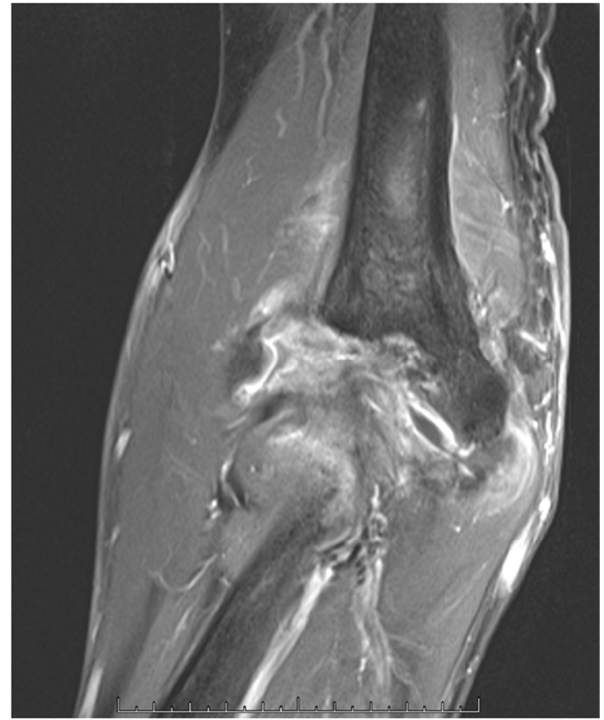A/P and lateral x-rays of the right elbow showed a sclerotic, fragmented appearance of the joint with calcifications. (Figure 2A & 2B). MRI revealed extensive destructive changes with irregularity of the medial and lateral humeral condyles and ulna. The most destructive changes were in the proximal radius with radial head dislocation. Soft tissue effusion was appreciated throughout the joint (Figure 3).



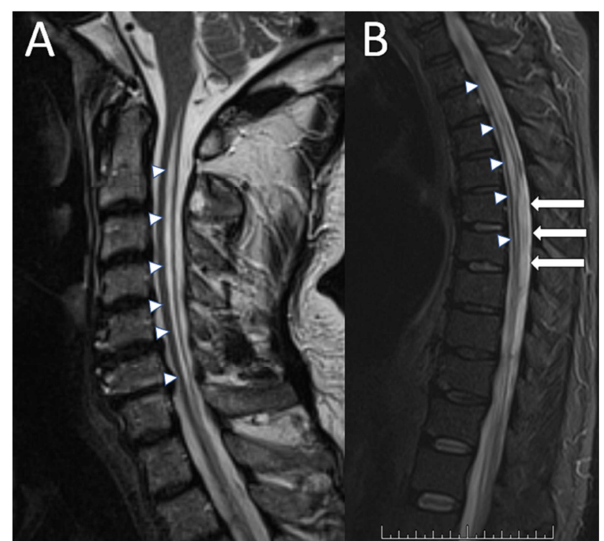
**Figure 2.** Lateral (A) and A/P (B) x-rays of right elbow showing sclerotic fragmented appearance of the joint with areas of calcification throughout. There is involvement on both sides of the joint surface without a specific defined lesion on either surface.

The differential diagnosis included septic arthritis, inflammatory arthropathy, soft tissue neoplasm, and NA. Septic arthritis was excluded as he was afebrile without leukocytosis and normal inflammatory markers. Core needle biopsy of the elbow soft tissue was negative for malignancy. MRI revealed a syrinx within the cervical and thoracic cord (Figure 4). There was an arachnoid cyst within the thoracic spinal canal causing ventral displacement of the cord. There was mild degenerative disc disease in the cervical spine without any cord compression. No evidence of Chiari

malformation, basilar invagination, or spinal tumors were observed. The patient underwent thoracic T4-T7 laminectomy and intradural exploration. A large, well-circumscribed arachnoid cyst was evident causing ventral displacement of the spinal cord (Figure 5A). Immediate restoration of CSF flow was visualized rostral and caudal to our resection cavity (Figure 5B). Pathology showed calcified arachnoid without evidence of malignancy or other process. There were no complications nor evidence of new deficits following surgery.

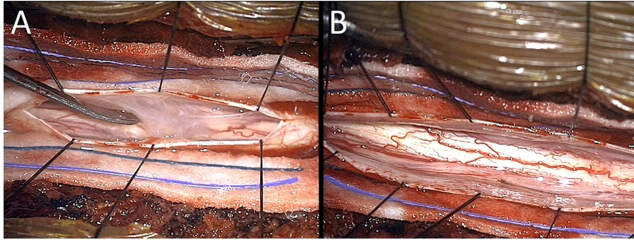


**Figure 3.** Contrast T1-WI MRI of right elbow showing extensive destructive changes with marked irregularity of the medial and lateral humeral condyle. The most pronounced destructive changes can be seen within the proximal radius with radial head dislocation.

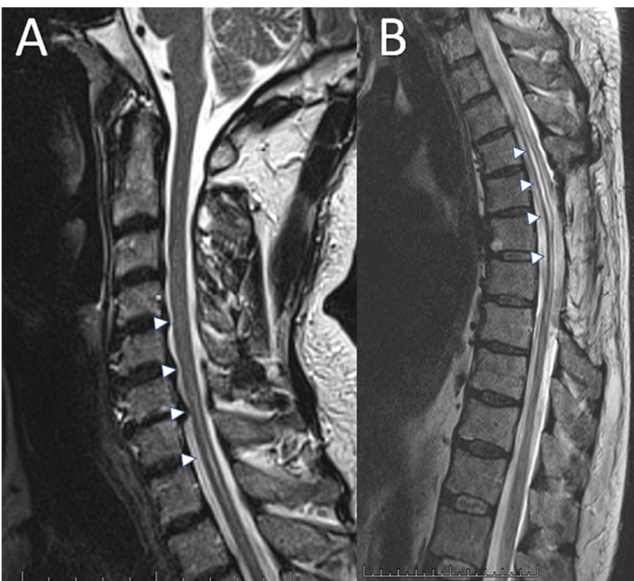


**Figure 4.** Preoperative T2 STIR MRI of the cervical (A) and thoracic spine (B) demonstrating a dilated syrinx within the spinal cord extending from the cervical spine to T6 (arrowheads). Note the arachnoid cyst displacing the cord ventrally (arrows).

The patient regained sensation to his extremities post-operatively and remained neurologically stable beyond 2-year follow-up. He had no new deficits or evidence of myelopathy. Repeat thoracic spine MRI at 3 months revealed reduction in the syrinx (Figure 6).



**Figure 5.** Intraoperative photograph demonstrating the arachnoid cyst with thickened arachnoid granulations (A). Note complete decompression and exposure of the spinal cord after arachnoid cyst removal (B).



**Figure 6.** Postoperative T2 STIR MRI of the cervical and thoracic spine demonstrating decompression of the dorsal arachnoid cyst, with reduction of the syringomyelia.

### 3. Discussion

Neuropathic joints develop in 25% of patients with syringomyelia, with the elbow representing the second most common location in the upper extremity, following the shoulder joint [1]. Only one case series reported the specific cause of syringomyelia to be arachnoid granulation tissue [5].

Early recognition of the pathogenesis (hyperemia, bone resorption, sclerosis) and radiologic patterns surrounding NA is critical in the preservation of joint function [1].

Radiographs reveal two patterns with NA: atrophic and hypertrophic. Hypertrophic patterns imitate osteoarthritis and are appreciated on radiographs of the ankle, knee, and elbow. Atrophic patterns mimic septic arthritis and are appreciated on the foot, hip, and shoulder [6]. Radiographs of joints with NA typically reveal joint destruction, disorganization, and effusion with osseous debris. Hypertrophic changes include osteophyte formation, heterotopic bone formation, or sclerosis.

Osteophytic formations seen in NA differ from osteoarthritis in that they form more acutely.

Radiographic characteristics of NA may resemble malignancy for which biopsy may be considered [1]. For comparison, the destructive pattern of NA commonly involves both distal and proximal portions of the bony articular surfaces, whereas chondrosarcoma typically spares one side. [6]. Fibrous dysplasia typically presents on CT scan with a “ground glass” appearance but may also show lytic lesions or bony expansion [7]. Giant Cell Tumors present with non-sclerotic margins surrounding an osteolytic lesion [7]. Aneurysmal Bone Cysts demonstrate “eggshell” like borders radiographically with a “ground glass” opacity and contrast enhancement on CT scan [7]. Chondromyxoid Fibromas show osseous destruction with lobulated margins [7].

Joint MRI is not needed for diagnosis but does reveal bony destruction, joint effusion, and edema of surrounding soft tissue [1]. Short TI Inversion Recovery (STIR) imaging may reveal the many micro-fractures that occur with disease progression [8]. Clinical suspicion of NA should prompt immediate cervical or thoracic spine MRI [1]. Syrinx will appear as central cord expansion and may reveal the cause of CSF obstruction. Consider myelography when MRI is equivocal [1, 5].

Aspiration aids in distinguishing NA from pathologies that require more immediate treatment, such as a septic joint or crystalline arthropathy [6].

Nonoperative treatment focuses on minimizing trauma, patient education, and maintaining function of the joint via rehabilitation and bracing [1, 9]. Although no specific rehabilitation plan is described for NA of the elbow, NSAIDs, joint aspiration, stretching, or strength exercises help to reduce pain and swelling [1]. In the past, immobilization was suggested; however, early mobilization is now encouraged for the elbow [1]. Bisphosphonates have not proven effective in long term management of NA [1, 10].

Blood glucose levels should be optimized for diabetic patients.

The surgical treatment of spinal obstruction in syrinx involves debridement of the obstruction or shunting to alleviate pressure. However, shunts have not demonstrated long term efficacy [5]. Joint surgery should not be considered until joint osteolysis has ceased and the syrinx has been treated [1].

Indications for orthopedic surgery include persistent pain, inability to use the arm for activities of daily living, and compromise of surrounding soft tissue. Neuropathic arthropathy is considered a contraindication to elbow arthroplasty due to risks of instability, infection, and lack of proprioceptive reflexes [1]. Although resection arthroplasty does not increase elbow stability it may reduce patient pain allowing for improved elbow performance [1]. Elbow arthrodesis (fusion) may establish fixed bone union, but patients are not able to compensate with motion from the shoulder or hand and upper extremity function remains poor [1]. Peripheral nerve decompression and neurolysis lead to functional recovery in patients with peripheral nerve

compression attributed to the neuropathic joint [1]. Although joint surgery may help select cases only early neurosurgical intervention has the potential to slow joint destruction, improve neurovascular function, and allow bone to heal [1].

## 4. Conclusion

We have reported a case of arachnoid granulations as a cause of syringomyelia leading to neuropathic arthropathy. While this case represents a rare etiology, radiographs are critical in narrowing the differential diagnosis and MRI is indicated to discover the underlying cause and guide management.

## References

- [1] Snoddy MC, Lee DH, Kuhn JE. Charcot shoulder and elbow: a review of the literature and update on treatment. *J Shoulder Elbow Surg.* 2017 Mar; 26 (3): 544-552. doi: 10.1016/j.jse.2016.10.015. Epub 2017 Jan 19. PMID: 28111181.
- [2] Buse AM, Mihai DA, Lupu L, Salmen T, Stegaru D, Radulian G. The Charcot Neuroarthropathy as Onset of Type 2 Diabetes - a Diagnostic Challenge. *Maedica (Bucur).* 2020 Mar; 15 (1): 122-125. doi: 10.26574/maedica.2020.15.1.122. PMID: 32419872; PMCID: PMC7221283.
- [3] Parida MK, Pattanaik SS, Panda AK, Das BK, Tripathy SR. Charcot arthropathy of elbow due to syringomyelia: a case series and systematic review of literature. *Clin Rheumatol.* 2022 Aug 22. doi: 10.1007/s10067-022-06332-7. Epub ahead of print. PMID: 35994178.
- [4] Flint G. Syringomyelia: diagnosis and management. *Pract Neurol.* 2021 Oct; 21 (5): 403-411. doi: 10.1136/practneurol-2021-002994. Epub 2021 Aug 25. PMID: 34433683.
- [5] Mallucci CL, Stacey RJ, Miles JB, Williams B. Idiopathic syringomyelia and the importance of occult arachnoid webs, pouches and cysts. *Br J Neurosurg.* 1997 Aug; 11 (4): 306-9. doi: 10.1080/02688699746087. PMID: 9337928.
- [6] Jones EA, Manaster BJ, May DA, Disler DG. Neuropathic osteoarthropathy: diagnostic dilemmas and differential diagnosis. *Radiographics.* 2000 Oct; 20 Spec No: S279-93. doi: 10.1148/radiographics.20.suppl\_1.g00oc22s279. PMID: 11046179.
- [7] Waldman S, Shimonov M, Yang N, Spielman D, Godfrey KJ, Dean KE, Phillips CD, Helman SN. Benign bony tumors of the paranasal sinuses, orbit, and skull base. *Am J Otolaryngol.* 2022 May-Jun; 43 (3): 103404. doi: 10.1016/j.amjoto.2022.103404. Epub 2022 Feb 26. PMID: 35246319.
- [8] Dogan BE, Sahin G, Yagmurlu B, Erden I. Neuroarthropathy of the extremities: magnetic resonance imaging features. *Curr Probl Diagn Radiol.* 2003 Nov-Dec; 32 (6): 227-32. doi: 10.1016/j.cpradiol.2003.08.004. PMID: 14647121.
- [9] Wawrzyniak A, Lubiowski P, Kordasiewicz B, Brzóška R, Laprus H. Shoulder arthropathy secondary to syringomyelia: case series of 10 patients. *Eur J Orthop Surg Traumatol.* 2022 Oct; 32 (7): 1275-1281. doi: 10.1007/s00590-021-03102-0. Epub 2021 Aug 24. PMID: 34430987.
- [10] Rastogi A, Bhansali A, Jude EB. Efficacy of medical treatment for Charcot neuroarthropathy: a systematic review and meta-analysis of randomized controlled trials. *Acta Diabetol.* 2021 Jun; 58 (6): 687-696. doi: 10.1007/s00592-020-01664-9. Epub 2021 Jan 13. PMID: 33439331.