

# Computed Tomographic Measurement of Thoracic Pedicle in Filipino Patients

Billy Francis Yu Hung, Paolo Antonio Florencio Castro

Department of Orthopaedics, East Avenue Medical Center, Quezon City, Philippines

## Email address:

[billyfrancishung@gmail.com](mailto:billyfrancishung@gmail.com) (B. F. Yu Hung)

## To cite this article:

Billy Francis Yu Hung, Paolo Antonio Florencio Castro. Computed Tomographic Measurement of Thoracic Pedicle in Filipino Patients. *International Journal of Neurosurgery*. Vol. 6, No. 1, 2022, pp. 19-22. doi: 10.11648/j.ijn.20220601.14

Received: April 24, 2022; Accepted: May 7, 2022; Published: May 12, 2022

**Abstract:** Knowledge of the morphometric measurements of Filipino thoracic spine pedicles would help the surgeons in determining the proper size and increase accuracy of pedicle screws placement during surgery to avoid complications. This study aims to measure the outer diameter, chord length and transverse angulation of the thoracic spine pedicles (T1-T12). A retrospective analysis of patients ages 18-85 years who underwent CT scan of the thoracic spine from January to December 2019. A total of 65 patients were included in the study. Pedicle morphology was measured with the following: transverse outer pedicle diameter, pedicle chord length, and transverse pedicle angle. TOPD was narrowest at the level of T4 ( $4.2 \pm 1.0\text{mm}$ ) followed by T5 ( $4.6 \pm 1.0\text{mm}$ ) and the largest TOPD at the level of T12 ( $8.7 \pm 2.1\text{mm}$ ). The largest PCL was at the level T12 ( $47.7 \pm 4.6\text{mm}$ ) and the shortest was at T2 ( $35.6 \pm 3.7\text{mm}$ ). The mean TPA largest at the level of T1 ( $35.8 \pm 6.1\text{mm}$ ) and progressively decreasing and slight increase at the level of T12 ( $6.3 \pm 3.5\text{mm}$ ). Men have larger pedicles as compared with women. It is recommended to use 4.5mm pedicle screw however it should be used with extra caution especially at mid thoracic level and among female patients.

**Keywords:** Thoracic Pedicle, Pedicle Morphology, Pedicle Diameter, Pedicle Length, Pedicle Angle, Pedicle Screw

## 1. Background

Posterior transpedicular construct or fixation is the most common form of thoracolumbar instrumentation. It is most often associated with posterior decompression [1]. Transpedicular screw fixation is frequently used to provide spinal stability in the setting of trauma, infection or tumor. It is also used in deformity correction in scoliosis. The pedicle screw size is based on the transverse and sagittal outer diameter (TOPD and SOPD) and chord length (PCL) of the pedicle and placement of the screw is determined by the transverse and sagittal angulation of the pedicle. Thoracic spine has the narrowest pedicle with a highly variable morphology among vertebral levels and individuals therefore a high accuracy of pedicle screw placement is required because pedicle wall break can lead to serious complications [2, 3]. Breakage of the pedicle wall medially risk injury to the dural sac or spinal cord while lateral wall breakage has higher risk of injuring the segmental vessels [3].

The morphometry of the thoracic spine pedicles has been documented among different races including Asian countries

(Korea, Japan, Singapore, Malaysia, and India) [3-7]. Knowledge of the morphometric measurements of Filipino thoracic spine pedicles would help the surgeons in determining the proper size and increase accuracy of pedicle screws placement during surgery to avoid serious complications intraoperatively.

The main objective of the study was to determine the transverse outer diameter, chord length and transverse angulation of the thoracic spine pedicles (T1-T12) among Filipino patients seen at the East Avenue Medical Center.

## 2. Methodology

A search in the Department of Radiology database for thoracic spine CT scans performed from January 2019 to December 2019 was done. All Filipino patients aged 18 - 85 years old were included in the study. All CT scans with normal thoracic vertebrae were included in the study. Radiographs with abnormal findings (fractures/dislocations, infections, malignancy, congenital anomalies) in the thoracic vertebrae were excluded from the study. CT scans that did not have the

patient's age nor gender or did not demonstrate the full extent of the thoracic spine from T1 to T12 were also excluded from the study. 65 patients (780 thoracic vertebrae/1560 pedicles) were entered in this study. All CT scans were performed using Philips Diamond Select Brilliance CT 64-slice. CT images (DICOM) were downloaded and viewed using RadiAnt DICOM Viewer 2020. Multiplanar reconstruction tool was used. Measurement of the outer diameter, chord length and transverse angulation of each thoracic spine pedicle were taken and recorded.

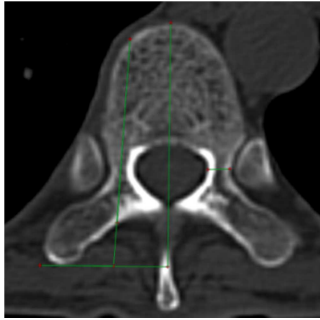


Figure 1. Adapted from Soh, et. al. (2011).

The thoracic spine pedicles were measured using the methods in the study of Soh, et. al [4]. The following parameters were measured: 1) transverse outer pedicle

diameter, 2) pedicle chord length, and 3) transverse pedicle angle. Measurements were made by the same researcher to ensure consistency. Statistical analysis was performed using Microsoft Excel 2016 for Mac with statistical significance being defined as a P value of less than 0.05. The mean and standard deviation was computed, and tabulated. Z test was used to analyze differences between gender and laterality.

### 3. Results

A total of 65 patients were entered in this study, in which there were 29 males and 36 females. The mean age was  $45.3 \pm 16.6$  years (range 18-83 years). There were 1560 pedicles (780 thoracic vertebrae) measured and the results of mean transverse outer pedicle diameter (TOPD), pedicle chord length (PCL) and transverse pedicle angle (TPA) are shown in table 1. The mean TOPD was smallest at T4 level ( $4.2 \pm 1.0$ mm) followed by T5 level ( $4.6 \pm 1.0$ mm) and the largest TOPD at the level of T12 ( $8.7 \pm 2.1$ mm). The smallest PCL was at the level T12 ( $47.7 \pm 4.6$ mm) and the shortest was at T2 ( $35.6 \pm 3.7$ mm). The mean TPA largest at the level of T1 ( $35.8 \pm 6.1$ mm) and progressively decreasing and slight increase at the level of T12 ( $6.3 \pm 3.5$ mm).

Table 1. Measurement of the Thoracic Pedicle (mm).

Vertebral Level (n = 984)	Transverse Outer Pedicle Diameter (mm) Mean $\pm$ SD	Pedicle Chord Length (mm) Mean $\pm$ SD	Transverse Pedicle Angle (mm) Mean $\pm$ SD
T1	$8.1 \pm 1.2$	$36.6 \pm 3.5$	$35.8 \pm 6.1$
T2	$6.4 \pm 1.1$	$35.6 \pm 3.7$	$19.7 \pm 6.7$
T3	$4.9 \pm 0.9$	$35.5 \pm 3.5$	$10.7 \pm 5.1$
T4	$4.2 \pm 1.0$	$36.1 \pm 3.7$	$7.8 \pm 3.9$
T5	$4.6 \pm 1.0$	$37.1 \pm 4.0$	$6.6 \pm 3.7$
T6	$4.9 \pm 1.0$	$38.0 \pm 3.8$	$5.7 \pm 2.6$
T7	$5.2 \pm 1.1$	$38.6 \pm 4.1$	$4.8 \pm 2.7$
T8	$5.3 \pm 1.1$	$38.9 \pm 4.4$	$4.0 \pm 2.4$
T9	$5.7 \pm 1.1$	$38.9 \pm 5.3$	$3.8 \pm 2.5$
T10	$6.4 \pm 1.4$	$39.6 \pm 4.6$	$4.0 \pm 3.8$
T11	$8.1 \pm 1.9$	$41.3 \pm 4.7$	$4.0 \pm 2.9$
T12	$8.7 \pm 2.1$	$47.7 \pm 4.6$	$6.3 \pm 3.5$

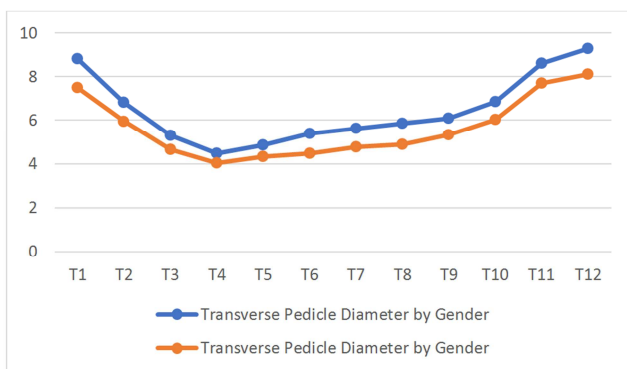


Figure 2. Transverse Outer Pedicle Diameter by Gender ( $p$  value  $< 0.05$ ).

Men have larger pedicles as compared with women. Figures 2 and 3 shows a comparison on the mean TOPD and PCL by gender. There was no significant difference found on

the measurements of the right and left pedicles, hence, the right and left pedicles were assumed to be from a separate individual to increase the sample size.

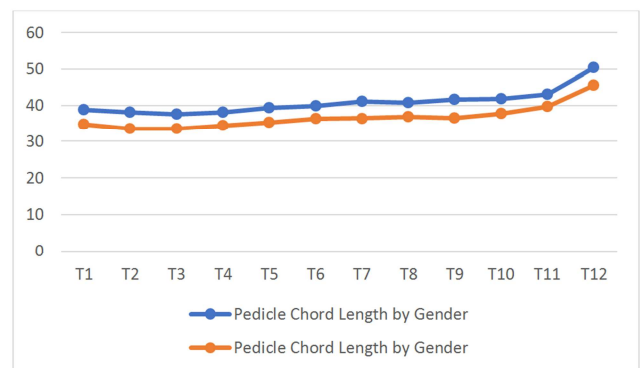
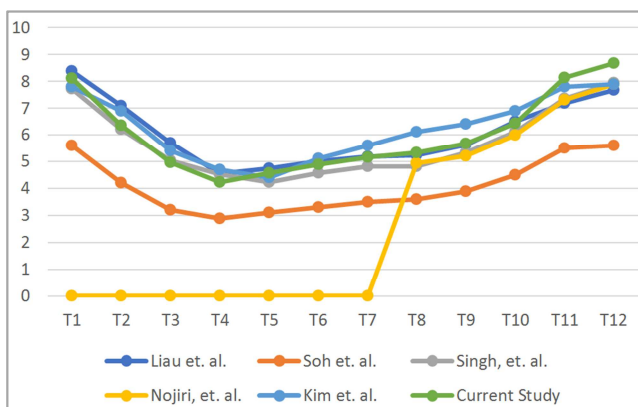


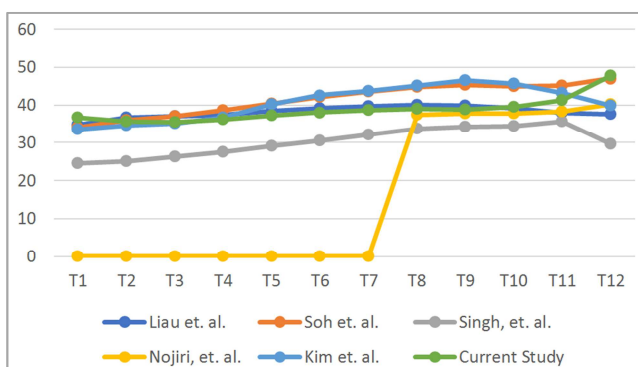
Figure 3. Pedicle Chord Length by Gender ( $p$  value  $< 0.05$ ).

## 4. Discussion

The pedicle is the strongest part of a vertebra and pedicle screws continue to offer the only three-column fixation available in the thoracolumbar spine. Advantages of transpedicular fixation of the spine include: rigid segmental fixation, improved fusion rates, reduction of deformity and maintenance of correction, earlier rehabilitation, and minimized use of postoperative bracing. Disadvantages and complications include: increased operative time and risk of infection, increased cost, risk of pedicle fracture, increased complication rates, dural tear, nerve root or spinal cord injury, anterior vascular injury, stress shielding and device-related osteoporosis, and risk of adjacent-level degeneration [1]. Transpedicular screw fixation was found to be superior than other spinal fixations [8-10]. Several studies were done which documented the morphology of the thoracic spine pedicles in Asian population (Korea, Japan, Singapore, Malaysia, and India) [3-7]. At present, there is no available literature regarding the morphology of the thoracic pedicles among Filipinos, hence this study aims to establish the morphology of the thoracic pedicle among Filipino population.



**Figure 4.** Comparison of Transverse Outer Pedicle Diameter among different Races.



**Figure 5.** Comparison of Pedicle Chord Length among different Races.

The narrowest mean outer diameter pedicle was recorded at the level of T4 ( $4.2 \pm 1.0\text{mm}$ ) followed by T5 ( $4.6 \pm 1.0\text{mm}$ ) and the mean diameter of the mid thoracic level were consistently greater than 4mm. A screw size of 4.5mm may

be used however with caution especially at the level of T4 and T5. Similarly, Soh, et. al. reported that the smallest TOPD was at T4 and T5 level, and the mean TOPD from T3 to T9 level was less than 4 mm. The thoracic pedicles among females were recorded to be 2.5 to 2.7mm at the T4 and T5 level. They suggested that care should be taken when inserting transpedicular screws at the mid thoracic level, especially in Asian women at the level of T4 and T5. The pedicle is able to contain a larger screw diameter than its outer diameter because of its ability to expand [11-12]. However, it is still important to note the possibility of pedicle wall break.

Figure 4 shows the mean TOPD and PCL from different Asian population studies and with the current study. According to a study by Zhuang, et. al., they suggested that screw length should be approximately 5mm shorter than the anticipated pedicle chord length to avoid anterior cortex breach which could result to visceral injury [13]. Based on the measurements gathered in this study, the recommended pedicle screw length are: 30mm for T1-T9 and 35mm for T10-T12. The recommended transverse pedicle angulation are:  $36^\circ$  for T1,  $20^\circ$  for T2,  $11^\circ$  for T3 and  $3-8^\circ$  for T4-T12, all are directed medially. On a study by Shetty, et. al., they recommended the use of 26mm screw length for the upper thoracic region and 36 to 37mm screw length for the lower thoracic region [14]. A similar study done by Pai et al., they formulated a chart based on their study and they recommended the use of 4.5mm screw size for all thoracic vertebra however the surgeon may use 3.5mm screw size for T4-T6 level. They also recommended the use of 25mm screw length for T1-T2, 30mm for T3-T5, 35mm for T6-T9 and 40mm for T10-T12 level [15].

Several techniques/methods may be used to minimize the risk of cortical breach during pedicle screw insertion like the use of “in-out-in” technique, medial margin targeting technique, and pedicle or transverse process hooks [15-16]. Use of navigation assisted spinal instrumentation may also minimize the risk of pedicle wall breakage [16].

## 5. Conclusions

Based on this study, it is recommended to use 4.5mm pedicle screw however it should be used with extra caution especially at mid thoracic level and among female patients. In cases where the outer diameter of the pedicles are extremely small, an “In-Out-In” technique maybe used to achieve a stable construct [14-15]. The optimal screw length are: 30mm for T1-T9 and 35mm for T10-T12. The recommended transverse pedicle angulation are:  $36^\circ$  for T1,  $20^\circ$  for T2,  $11^\circ$  for T3 and  $3-8^\circ$  for T4-T12, all are directed medially.

## Conflict of Interest

The authors declare that they have no competing interests.

## References

- [1] Truumees, E. Thoracic And Lumbar Instrumentation: Anterior And Posterior. In: Garfin, SR, Eismont, FJ, Bell, GR, Fischgrund, JS, Bono, CM, Editors. Rothman-Simeone And Herkowitz's The Spine. 7<sup>th</sup> Ed. Philadelphia: Elsevier, Inc.; 2018. P. 1187-1217.
- [2] Knez D, Vrtovec T. Computerized Three-Dimensional Pedicle Morphometry from Computed Tomography Images of the Thoracic Spine. *Image Analysis and Stereology*. 2020; 39 (2): 101–9.
- [3] Liao KM, Yusof MI, Abdullah MS, Abdullah S, Yusof AH. Computed Tomographic Morphometry of Thoracic Pedicles Safety Margin of Transpedicular Screw Fixation in Malaysian Malay Population. Vol. 31, *Spine*.
- [4] Layeeque KM, Karambelkar RR, Shewale AD. Pedicle Dimensions of Thoracic Vertebrae in Maharashtra Population. *Journal of Evolution of Medical and Dental Sciences*. 2014 Nov 25; 3 (65): 14146–53.
- [5] Soh TLT, Kho KC, Lim ZK, Tandon AA, Kaliya-Perumal AK, Oh JYL. Morphological Parameters of the Thoracic Pedicle in an Asian Population: A Magnetic Resonance Imaging–Based Study of 3324 Pedicles. *Global Spine Journal*. 2021 May 1; 11 (4): 437–41.
- [6] Nojiri K, Matsumoto M, Chiba K, Toyama Y. Morphometric Analysis of the Thoracic and Lumbar Spine in Japanese on the Use of Pedicle Screws. *Surgical and Radiologic Anatomy*. 2005 Apr; 27 (2): 123–8.
- [7] Kim JH, Choi Gm, Chang IB, et al. Pedicular and Extrapedicular Morphometric Analysis In The Korean Population: Computed Tomographic Assessment Relevance To Pedicle And Extrapedicle Screw Fixation in the Thoracic Spine. *Journal of Korean Neurosurgical Society*. 2009 Sep; 46 (3): 181-188.
- [8] Muteti E, Teaching M, Hospital R, ElBadawi M. A CT-Based Study of the Thoracic Spine Pedicle and Pedicle-Rib Unit Morphometry in a Kenyan Population. Vol. 13, *East African Orthopaedic Journal EAOJ*. 2019.
- [9] Hackenberg L, Link T, Liljenqvist U. Axial and Tangential Fixation Strength of Pedicle Screws Versus Hooks in the Thoracic Spine in Relation to Bone Mineral Density. *Spine (Phila Pa 1976)*. 2002; 27: 937-942.
- [10] Suk SI, Kim WJ, Lee SM, Kim JH, Chung ER. Thoracic Pedicle Screw Fixation in Spinal Deformities: Are They Really Safe? *Spine (Phila Pa 1976)*. 2001; 26: 2049-2057.
- [11] Misenhimer GR, Peek RD, Wiltse LL, Rothman SL, Widell EH Jr. Anatomic Analysis of Pedicle Cortical and Cancellous Diameter as Related to Screw Size. *Spine (Phila Pa 1976)*. 1989; 14: 367-372.
- [12] Cahill P, Rinella AS, Ghanayem A, et al. P8. Thoracic Pedicle Expansion After Pedicle Screw Insertion in a Pediatric Cadaveric Spine: A Biomechanical Analysis. *Spine J*. 2004; 4 (5 Suppl): S93.
- [13] Zhuang, Z, Chen, Y, et al. Thoracic Pedicle Morphometry in Different Body Height Population. A Three Dimensional Study Using Reformatted Computed Tomography. *Spine*: November 15, 2011 – Volume 36 – Issue 24 – p E1547-E1554. doi: 10.1097/BRS.0b013e318210f063.
- [14] Shetty, A, Avadhani, R, et al. Thoracic Pedicle Morphometry Study on Cadaver and CT Scan with Its Clinical Applications. 2019; Original Research Article, 7 (1), 6089–6100. <https://doi.org/10.16965/ijar.2018.414>
- [15] Pai, B. S., Gangadhara, Nirmala, S., Muralimohan, S., & Varsha, S. M. (2010). Morphometric analysis of the thoracic pedicle: An anatomico-radiological study. *Neurology India*, 58 (2), 253–258. <https://doi.org/10.4103/0028-3886.63808>
- [16] Verma, V., Santoshi, J. A., Jain, V., Patel, M., Dwivedi, M., Nagar, M., Selvanayagam, R., & Pal, D. (2020). Thoracic Pedicle Morphometry of Dry Vertebral Columns in Relation to Trans-Pedicular Fixation: A Cross-Sectional Study From Central India. *Cureus*. <https://doi.org/10.7759/cureus.8148>