

Penetrating Brain Injury by an Iron Bar in a Child

**Yameogo Wendlasida Serge Pacome Arnauld^{1,*}, Zabsonre Denlewende Sylvain²,
Taoko Lassane 1^{er} Jumeau², Jemel Hafedh³, Kabre Abel²**

¹Department of Surgery, Regional Hospital Center University of Ouahigouya, Ouahigouya, Burkina Faso

²Department of Neurosurgery, Hospital Center University Yalgado Ouedraogo, Ouagadougou, Burkina Faso

³Department of Neurosurgery, University of Tunis El Manar, Tunis, Tunisia

Email address:

pacomesegey@yahoo.fr (Y. W. S. P. Arnauld), szabsonre@gmail.com (Z. D. Sylvain), astaojum@gmail.com (T. L. 1^{er} Jumeau),
hafedh.jemel@yahoo.fr (J. Hafedh), kabrel@yahoo.fr (K. Abel)

*Corresponding author

To cite this article:

Yameogo Wendlasida Serge Pacome Arnauld, Zabsonre Denlewende Sylvain, Taoko Lassane 1^{er} Jumeau, Jemel Hafedh, Kabre Abel.

Penetrating Brain Injury by an Iron Bar in a Child. *International Journal of Neurosurgery*. Vol. 5, No. 1, 2021, pp. 33-37.

doi: 10.11648/j.ijj.20210501.18

Received: April 12, 2021; **Accepted:** May 5, 2021; **Published:** May 14, 2021

Abstract: *Introduction:* Penetrating brain injury is not common among the civilian population and it is rare in children. The use of computed tomography is essential for decision-making in the management of patient's with penetrating brain injury. Here, we report a case about the management of a penetrating brain injury by an iron bar in a child after an assault. *Case report:* We describe a case of a 5-year old male, who was admitted to the trauma emergency unit of the Hospital Center University Yalgado OUEDRAOGO on April 1, 2019 with an iron bar stuck into the head, one hour after the injury. The patient was aware. He was complained about headaches and was agitated. His vitals were stable. At the initial examination, there was no neurological disorder. Cranial computerized tomography showed iron bar planted deep into the left frontal lobe and directed obliquely into the right frontal lobe. Patient's agitation has led to a displacement of the iron bar. New examination has revealed right hemiparesia. An emergency surgery was performed. The patient was discharged without any complications. *Conclusion:* Penetrating brain injuries by an iron bar are rare in children. Children must be kept calm in order to avoid the displacement of the iron because it can increase the risk of cerebral damage. An earlier management provides better prognosis.

Keywords: Penetrating Brain Injury, Child, Iron Bar

1. Introduction

Penetrating head trauma or penetrating brain injury is traumatic brain injury which is not the result of a blunt mechanism [1]. It occurs when the cranium and its contents are breakthrough by a projectile or nonprojectile object [2].

In the military, penetrating brain injury (PBI) is encountered mainly during wartime. Penetrating brain injury is not common among the civilian population and it is mostly caused by violence, suicide, road traffic accident, and work accidents mechanism [3]. Penetrating head injury is unusual wound. It constitutes about only 0.4% of all head injuries mechanism. It is rare in children [2, 4]. Pediatric penetrating head injury caused by traditional agriculture tool, metal nails and rods, pencils, kitchen

utensils, power tools, stab wounds, and gunshot wounds (GSWs) have been reported in the literature [1, 4-6]. An earlier management of the penetrating head injuries is necessary in order to prevent complications and to reduce the risk of morbidity and mortality. Imaging is essential for decision-making in the management of the patients with penetrating head injuries. Computed tomography (CT) remains the 'gold standard' imaging tool about wound information [7-9]. Here, we report a case about the management of a penetrating brain injury by an iron bar in a child after an assault.

2. Case Report

We report a case of a 5-year old male child, who was admitted to the trauma emergency unit of the Hospital Center

University Yalgado OUEDRAOGO on April 1, 2019 with an iron bar stuck into the head. During a fight, a kid had struck a blow with a metal construction material on the forehead. There was no history of loss of consciousness, vomiting or convulsions. At admission, 1 hour after the injury, the patient was complained about headaches and was agitated. His vitals were stable (temperature: 37°C, pulse rate: 87/min, heart rate: 87/min blood pressure: 110/60 mm Hg, and respiratory rate: 16/min). The pupils were equal in size and reacting normally to light. The Glasgow coma score (GCS) was 15/15. There was no motor or sensory deficit. The iron bar was implanted through the left side forehead bone (shown in Figure 1).

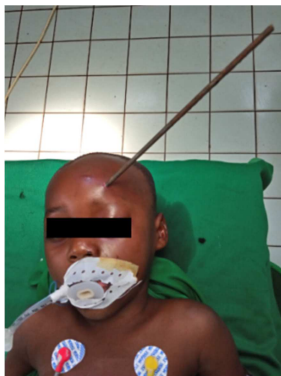

Figure 1. Pre-operative anterior view of the patient showing an iron bar stuck into the left forehead.

Cranial computerized tomography (CT) showed iron bar planted 9cm deep into the left frontal lobe, and directed obliquely, downward, crossing the midline and the cerebral anterior falx and into the contralateral right frontal lobe. The extent of brain damage could not be ascertained on the CT images because imaging was severely impaired by metallic artifact (shown in Figure 2.). CT angiography was not available in our hospital.

An analgesic in intravenous route (paracetamol) was administered in order to reduce pain and agitation. Despite that, patient's agitation has continued and this has unfortunately led to a displacement and a small withdrawal of the iron bar. A new neurological examination has revealed right hemiparesia with a muscle strength grading at 4/5 in the limbs.

Antibiotics and antiepileptic prophylaxis were administered preoperatively. An emergency surgery was performed in the operating theater 7 hours after the injury. A transversal incision was made on both side of the bar. The placement of a self-retaining retractor has allowed to expose the bone defect around the bar. The realization of a craniectomy was not necessary. The iron rod has been carefully removed. There was not active bleeding. Necrotic brain tissue and bone fragments were removed. The cavity was repeatedly irrigated with hydrogen chloride solution and isotonic saline solution. Then, dura mater and the skin were closed. The Figure 3. shows the suture of the operative wound and the Figure 4. shows the iron bar removed by surgery.

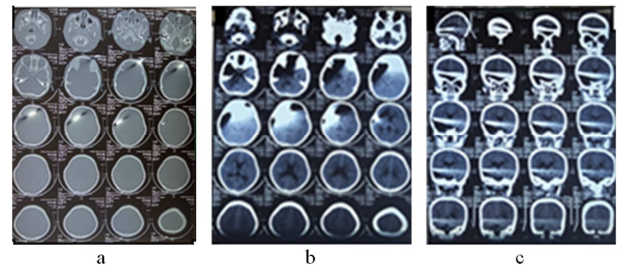


Figure 2. Pre-operative CT scan images showing impairment by metallic artifact. (a) CT scan bone window axial cut. (b) CT scan parenchymal window axial cut. (c) CT scan parenchymal window coronal cut.

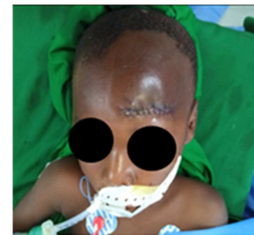

Figure 3. Post-operative anterior view showing the suture of the operative wound.



Figure 4. Iron bar removed by surgery.

The patient was then admitted to the intensive care unit. Postoperatively, a large spectrum antimicrobial therapy in intravenous route (ceftriaxone 2g q 24h for 10 days, metronidazole 200mg q 8h for 10 days and gentamycin 80 mg q 24 h for 5 days) was administered because of the high risk of intracranial septic complications. Prophylaxis for seizures (sodium valproate 200mg q 8h for 1 month) and tetanus (antitetanus immunoglobulin and antitetanus vaccine) were administered. On the second postoperative day, control CT was done in order to look for intracranial hematoma. CT has revealed a cerebral edematous and hemorrhagic contusion in the line of the wound track (shown in Figure 5.).

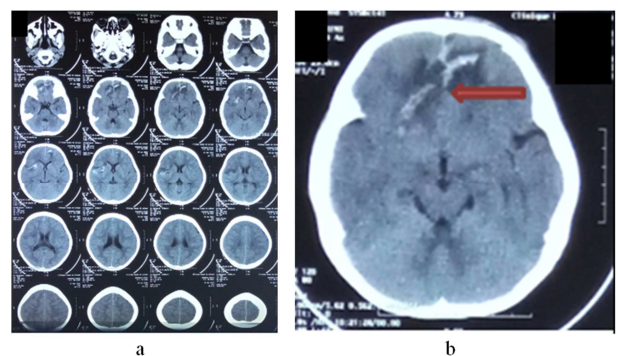


Figure 5. (a), (b) second post-operative day CT scan parenchymal window axial cut showing a cerebral edematous and hemorrhagic contusion around the tract traverse by iron rod. (b) The red arrow shows the line of the wound track.

On the tenth day, the patient was discharged without any complications. There was also no sign of infection and the neurological status was unchanged.

At the first month follow-up, the patient's neurological status was improved with a muscle strength grading normal at 5/5 in the limbs. At the second year follow-up, there has been no report of seizure or infection. His neurological status was normal and there was no neuropsychiatric change or growth disturbance. Police investigation ruled out the possibility of child abuse.

3. Discussion

In our study, we report a case of a penetrating head injury involving in a child by an iron bar after an assault. Penetrating head injury is rare in children [4, 5]. The incidence of penetrating head injury among the pediatric population is unknown [10]. The percentage can be estimated at 1.2% [11]. However, Muballe et al. [10] have reported that pediatric penetrating head injuries represented 7.38% of all pediatric head injury admissions in children. Most of children injuries are due to motor vehicle accidents and falls [5, 12-15]. Assaults are less encountered in children. Bahloul et al. [12], and Alhabdan et al. [15] have respectively reported 0.7% and 1.4% as the percentage of violence among the cause of pediatric head injury. In our study, the penetrating head injury has been caused by stabbing by an iron bar.

Related to the study of ballistics, low-velocity projectiles injuries such as iron bar differs from medium- and high-velocity projectiles injuries such as gunshot or missiles [5]. Kinetic energy is represented by the equation $1/2mv^2$. In medium- and high-velocity projectiles, the kinetic energy transferred to the tissue results in radial stretching and cavitation that cause shear forces leading to significant, widespread axonal disruption as well as the endangering of vascular structures [16]. Low-velocity injuries don't cause concentric zones of cavitations and necrosis. Objects caused this type of injuries endanger the axons and vascular structures in the penetrating track by direct anatomic disruption. The damage is predominantly restricted to hemorrhagic infarction in the line of the wound track. Contrecoup injuries and diffuse axonal injury are very unlikely encountered. The prognosis is usually favorable when vital centers and large vessels are not damaged [5]. Incurred damage can occur when the brain stem or direct lacerations of a major vessel are involved [10, 16, 17].

Initial examination of our patient don't reveal neurological disturbance. The motor deficit occurred after displacement of the iron bar. If the foreign body is still retained, care should be taken to minimize his movement [16]. However, it is often difficult to keep a child calm without sedation. Sedation is necessary to avoid any additional injury when the patient is agitated and moved [3]. The movement of the iron bar could induce new brain damage. Neurological sequelae at admission after penetrating head injuries included cranial nerve deficits, motors disturbances such as hemiparesis or hemiplegia, languages disturbances such as aphasia or dysphasia, visuals disturbances such as blindness, cerebellar ataxia, and seizures

[10, 17]. The least morbidity and mortality are encountered in frontal stabs [17].

Cranial computerized tomography (CT) has been used for the evaluation of the injury because the CT angiography was not available in our hospital. CT scans are the exam of choice for the radiological study [2, 8, 16, 18]. In the patient with non-metallic injury, MRI may be superior to CT scan in the radiological study [2, 8, 18]. However, brain CT angiography is recommended for evaluation of cerebrovascular insult. According to the literature, the rate of vascular injury in penetrating head injury is 5-40% [2, 3, 16, 17]. If available, the use of intraoperative CT can reduce or even avoid surgical revisions due to postoperative complications [19]. When imaging is impaired by the metallic artifact of the foreign objects, the digital subtraction angiography (DSA) is necessary to describe vascular damage [16].

In our case, the surgery has been performed 7 hours after the injury. The dura mater and the skin were closed after the removal of necrotic brain tissue and bone fragments. Prompt surgical intervention is recommended in patient with penetrating head injury [8, 19]. According to the literature, the surgery in patient with craniocerebral wound must ideally be performed urgently but a delay of 24 to 48 hours must be justified [20]. The aim of the surgical intervention in patient with penetrating head injury is the removal the penetrating item from the brain parenchyma, the debridement of the necrotic brain tissue, the removal of accessible bone or foreign body fragments and other potential contaminants to prevent infections, the evacuation of any hematoma, the realization of a secure hemostasis and the realization of a meticulous dural closure to prevent cerebrospinal fluid leakage and a meticulous scalp closure [2, 5, 8,]. In the literature, there is no answer regarding the choice of the best surgical techniques between craniotomy and craniectomy [1, 8, 18]. Because of the size of bone defect, the iron bar has been removed without performing craniotomy or craniectomy.

Antibiotics and antiepileptic were administered preoperatively and postoperatively. Antitetanus immunoglobulin and antitetanus vaccine were administrated and hydrogen chloride solution was used for the wound debridement. In order to prevent or to minimize infections complications, anti-tetanus serum and antibiotics can be administrated, and wound debridement by oxygen peroxide can be carried out [17]. According to the literature, antibiotic therapy should be initiated on admission. However, there are no data about the continuation of antibiotics after surgical removal [1, 8, 17, 18, 19]. In our case; we have giving 3 antibiotics therapy in intravenous route for a total duration of 10 days and there was no history of post-operative meningo-encephalitis. The goal of prophylactic antiepileptic drugs in the early stage of the injury is to reduce the incidence of post-traumatic epilepsy [19]. In case of brain injury, about 30-50% of patients may develop seizures. However, prophylactic antiepileptic treatment is controversial [8]. Because of this result, we routinely administer antiepileptics in craniocerebral wound in our practice. In our case, there was no history of post-operative epilepsy.

There was no post-operative complication in our case. The main complications after penetrating head injury surgery are infection such as local wound infection, meningitis, brain abscess formation and seizures [19]. Vascular complications are frequently encountered in cases of penetrating head injury. According to the literature, it ranges from 5 to 40% [18]. Complications such as cerebrospinal fluid fistula and neuro-endocrine dysfunction are less common [1, 5]. In our study, we have decided to prevent post-operative complication such as infectious, seizures and cerebrospinal fluid fistula complications by the administration of antibiotics, antiepileptics and by performing a meticulous dural and skin closure. There were no signs in our case that evoked a vascular and neuroendocrine complication.

4. Conclusion

To conclude, penetrating head injuries by an iron bar are not common in children. Assaults are less encountered in the pediatric population. Children must be kept calm before the surgery in order to avoid the displacement of the iron because this displacement can increase the risk of cerebral damage. CT scan is the gold standard imaging tool for a better assessment of intracranial lesion. An earlier management helps to avoid or to reduce complications and this provides a better prognosis.

Consent for Publication

Written informed consent was obtained from the parent of the patient for publication of this case report and any accompanying images.

Conflict of Interest Statement

The authors have no conflicts of interest to declare.

Authors Contributions

All the authors contributed to this work.

Funding Sources

There was no funding source in the preparation of data or the manuscript.

Acknowledgements

Thanks to Bama Armel Donald and Nébié Eric who provided help during the research.

References

- [1] Fahde Y, Laghmari M, Skoumi M. Penetrating head trauma: 03 rare cases and literature review. *Pan Afr Med J.* 2017; 28: 305.
- [2] Lan ZG, Richard SA, Li J, Yang C. Nonprojectile penetrating iron rod from the oral cavity to the posterior cranial fossa: a case report and review of literature. *Int Med Case Rep J.* 2018; 11: 41–45.
- [3] Tabibkhoei A, Taheri M, Rohani S, Chanideh I, Rahatlou H. Penetrating brain injury with a metal bar and a knife: Report of two interesting cases. *Neuroradiol J.* 2017; 0 (00): 1–4.
- [4] Badhiwala JH, Blackham JR, Bhardwaj RD. Neuropsychiatric changes following penetrating head injury in children. *Surg Neurol Int.* 2014; 5: 154.
- [5] Karim T, Topno M. An unusual case of penetrating head injury in a child. *J Emerg Trauma Shock.* 2010; 3: 197–198.
- [6] Zabsonre DS, Sanou A, Dao I, Alzouma H, Yameogo P, Lankoande H, et al. Penetrating Head Injury by Traditional Agriculture Tool. *Ann Emerg Surg.* 2017; 2 (4): 1019.
- [7] Mathew P, Nott DM, Gentleman D. Safe management of paediatric penetrating head injury without a CT scanner: A strategy for humanitarian surgeons based on experience in southern Afghanistan. *Ann R Coll Surg Engl.* 2016; 98: 198–205.
- [8] Sonmez E, Borcek AO, Guven C, Hasturk AE. An Iron Rod Stuck in the Right Motor Cortex. *Turk Neurosurg.* 2012; 22 (6): 772–774.
- [9] Yusuf AS, Mahmud MR, Alfin JD, Adeleke NA. Clinical presentation and outcome of impalement craniocerebral injuries – a case series. *J West Afr Coll Surg.* 2017; 7 (2): 112–123.
- [10] Muballe KD, Hardcastle T, Kiratu E. Neurological findings in pediatric penetrating head injury at a university teaching hospital in Durban, South Africa: a 23-year retrospective study. *J Neurosurg Pediatr.* 2016; 18: 550–557.
- [11] Murgio A. Epidemiology of traumatic brain injury in children. *Rev Esp neuropsicol.* 2003; 5 (2): 137–161.
- [12] Bahloul M, Chelly H, Gargouri R, Dammak H, Kallel H, Ben Hamida C et al. Traumatismes crâniens chez l'enfant dans le sud tunisien profil épidémiologique, manifestations cliniques et évolution. A propos de 454 cas. *Tunis Med.* 2009; 87 (01): 28–37.
- [13] Gizaa CC, Mink RB, Madikians A. Pediatric traumatic brain injury: not just little adults. *Curr Opin Crit Care.* 2007; 13: 143–152.
- [14] Araki T, Yokota H, Morita A. Pediatric Traumatic Brain Injury: Characteristic Features, Diagnosis, and Management. *Neurol Med Chir (Tokyo).* 2017; 57: 82–93.
- [15] Alhabdan S, Zamakhshary M, AlNaimi M, Mandora H, Alhamdan M, Al-Bedah K. Epidemiology of traumatic head injury in children and adolescents in a major trauma center in Saudi Arabia: implications for injury prevention. *Ann Saudi Med.* 2013; 33 (1): 52–56.
- [16] Young M, Putty M, Finneran MM, Johnson R, Schaible K, Farhat H. Multidisciplinary Management of Lowvelocity Nonmissile Penetrating Head Injuries. *Cureus.* 2020; 12 (3): e7388.
- [17] Miscusi M, Arangio P, De Martino L, De-Giorgio F, Cascone P, Raco A. An unusual case of orbito-frontal rod fence stab injury with a good outcome. *BMC Surg.* 2013; 13: 31.

- [18] Diyoraa B, Kotechaa N, Mullaa M, Detheb S, Bhendea B, Patila S. Perforating head injury with iron rod and its miraculous escape: Case report and review of literature. *Trauma Case Rep.* 2018; 14: 11–19.
- [19] Shi L, Sun Y, Chen L, Xue H, Zhang W, Yang H. Diagnosis and treatment of a penetrating brain injury caused by a welding electrode a case report. *Medicine.* 2019; 98: 10 (e14528).
- [20] Salaou O, Naja A, Aboudou Y, Ibahiouin K, Elkamar A, El Azhari A. Prise en charge des plaies craniocérébrales de l'enfant (A propos de 60 cas). *Afr J Neurol Sci.* 2006; 25 (1): 50-58.